

Clear aligners, dentofacial orthopedics, physics and supercorrection prescription biomechanics. A meeting of the minds

John C. Voudouris, John Dean Voudouris, Olivier Nicolay, Barry Glaser, John Nicozisis, Gina Theodoridis, Roberto Carrillo, Mazyar Moshiri, and Mohamed Masoud

Introduction

Τα πάντα ρει. Everything flows.
(nothing is permanent except change)

—Heraclitus

How can more predictable finishing be achieved consistently with aligners in highly complex malocclusions? This aligner update covers a simple prescription with three differential supercorrections, dentofacial orthopedic applications with aligners, and six new aligner innovations built upon a scientific, physics-based foundation of aligner biomechanics. Here we categorize in a systemized manner the biomechanical concepts and supercorrections for aligners by applying the literature with extensive illustrations. We then complemented these principles with actual clinical treatments recruiting several other aligner experts

recognized internationally for their specialized techniques and finishing.

There are three different levels of basic supercorrections for different malocclusions as a guide because while aligner companies have now taken the first step to acknowledge that “actual clinical results may vary,” refinements are at minimum both undesirable and costly to patients, and orthodontists. This is on account of added procedures and expenses, including to suppliers in terms of free aligners, at the start. We understand the limitations of semi-elastic thermoplastic and agree clinical results also vary partly because virtual software animations are largely set-up remotely by technicians and in isolation away from our patients. *What is observed on the animation using algorithms clearly is not fully expressed in complex treatments clinically* from several systematic reviews, and other high quality studies.¹⁻³ For this reason, *our virtual treatment plans (VTPs) need to look irregular to alter the semi-elastic thermoplastic for superperformance* in highly complex treatments. Certainly, orderly arranged checklists also help the clinician approve VTPs efficiently for more predictable results. This reduces treatment over-runs and the massive number of unnecessary, unrecyclable refinement plastics in the hundreds of thousands each year that is good for the environment and planet. The new challenge is to minimize the percentage of refinements annually in our clinics to a single digit that is attainable.

Three differential supercorrections have been applied to complex malocclusions to show how this new set of compensations work to produce more accurate and precise finishing. The honeymoon with aligner digitalization is over. It appears clear today that orthodontists fully equipped with established biological and biomechanical concepts and principles can contribute significantly more to take full control of

Private orthodontic practice for 34 years combining full aligner treatment, Instructor Graduate Orthodontic Program, University of Toronto and Visiting Scholar New York University, Division of Biological Sciences, AAO Milo Hellman Research Award Recipient for Condylar-Glenoid Fossa and Neuromuscular Activity with Mandibular Advancers, Toronto, ON, Canada; Research Student and Biomechanics Illustrator using Adobe® Illustrator and Photoshop, Toronto, ON, Canada; Chairperson of the Department of Orthodontics, New York University, NY, NY, United States; Private orthodontic practice Cortlandt Manor, NY, United States; Invisalign Faculty, Princeton, NJ, United States; Member of the Board of the European Aligner Society, Private orthodontic practice Athens, Greece; Private orthodontic practice San Pedro Garza Garcia, Mexico, Adjunct Assistant Professor, Department of Orthodontics, Texas A&M University, Dallas, TX, United States; Invisalign Faculty, Saint Louis University Faculty, St. Louis MO, United States; Associate Professor of Developmental Biology, Harvard School of Dental Medicine, private orthodontic practice, Falls Church, and Herndon, VA, United States.

Corresponding author. E-mail: jvoud@me.com

© 2021 Published by Elsevier Inc.

1073-8746/12/1801-30.00/0

<https://doi.org/10.1053/j.sodo.2021.11.002>

treatment planning with aligner programming and design. While the clinical case studies are useful for the effectiveness of aligners more randomized efficacy studies of working supercorrection techniques will follow in the future.

Second, this paper demonstrates that previously complex dentofacial orthopedics are possible consistently with aligner therapy. It is critical to realize collectively that we clearly cannot continue to focus on the teeth alone. While esthetics matter, orthodontists are not dental cosmetologists. We need to apply our extensive knowledge of facial growth and development established for over a century for timing dentofacial orthopedics, genetics, etiology, muscle activity, biology of tooth movement, and dental positions over basal bone effectively. We know this reduces relapse found in high quality investigations. After all, when there is a tag-team battle in the clinical arena between a genetic or environmental etiology and muscles, bones and teeth, etiology and muscles win. Addressing these factors with aligners shown here can significantly reduce re-makes and refinements. This includes a sound *prior* diagnosis applying simple cephalometric measurements directly into the virtual treatment plan.

The third part of this paper takes an organized, physics-based approach to understanding aligner biomechanics with structured guidelines. As a main goal it is possible to plan and program aligner treatment with much greater predictability for higher finishing results as shown from the experts' clinical treatments. In summary, this paper reviews 53 aligner guidelines with differential supercorrections, aligners for dentofacial orthopedics and biomechanics to update and assist your aligner treatment objectives, treatment planning, and your retention.

John Voudouris
University of Toronto, New York University

This is a clinical aligner update using a scientific physics-based organization of biomechanical principles⁴⁻⁶ systematically arranged for aligner techniques such as differential supercorrection to overcome biological and mechanical limitations. Examples of how aligner biomechanics can help orthodontists in the clinic includes the six classifications of appropriate bond or attachment

geometries and describes the *dominant* moments of forces, and *dominant* moments of couples involved with aligner design. Biomechanics can also especially assist aligner designing to reduce aligner gap complications found typically at the upper lateral incisors between the thermoplastic and the incisal edges that are chronic, common, and frequent. The six reasons for gaps are listed and reviewed to generally help prevent contributions to refinements.⁷⁻¹² This includes recognizing the benefit of a *beveled gingival bond, that is flash-free* for a crowded and palatally displaced upper lateral incisor and that it *tips with aligners from a center of rotation*⁶ resulting in relative intrusion away from the aligner. It helps to pre-plan *space first* and *add labial root torque stepwise* with tipping and *good compliance*.

Scientific investigations have been reviewed on efficacy with limitations of aligners¹³⁻²⁴ for over 16 years to try here to set specific guidelines on different supercorrections and specific biomechanics. Semi-elastic thermoplastic forces and moments²⁵⁻²⁶ are known to reduce over 1-3 days,²⁷⁻³¹ deform, wear against attachments, and are subject to dental lag.³² This is in addition to the limitations of the surrounding biological structures such as the neuromusculature, density and turnover of bone for adults compared to teens. With the awareness of these limitations, different compensatory adjustments or differential supercorrections were developed for different complex malocclusions for *irregular* aligner programming. It is *differential* because each patient and orthodontic condition is individual. Scientific evidence-based data has demonstrated that severe dental rotations require 110% compensation with 110% Super Class I distalization, while heavy clenching in skeletal deep bites (requiring Progressive Posterior Extrusion) and incisor supra-eruption needs to increase supercorrection to an average of 150% for overbites <50% and 200% supercorrection for deep overbites ≥50%.

For Class II division 2 incisor torque control, and in congenitally missing upper lateral incisors and mesially positioned upper canine roots, supercorrection in thermoplastic ramps up to a higher average 200% to produce adequate space for dental implants with aligners. This same 200% supercorrection is used in converging lower incisors, and in a T-design of attachments to produce 4 forces in 2 planes of space for each dental unit by working on

labial and lingual bonds respectively for more effective root angulation. The simple placement of a limited number of lingual attachments is indicated in supercorrection.

Aligner applications are also extended to produce seven significant dentofacial orthopedic effects here. Pronounced mandibular autorotation in two open bite treatments both with and without TADs for bodily en masse intrusion *controls the vertical dimension for horizontal Class II changes*. This includes Progressive Posterior Intrusion supercorrected on average 200% in conjunction with 12 new aligner tongue trainers, and aligner bite blocks.

Reverse pull headgear and aligners with inverted bite ramps at the lingual of the lower incisors facilitate RME maxillary expansion with advancement in Class III treatments. A review is also included of the 12 skeletal, dental and other contributions of Invisalign® Mandibular Advancers (MA)TM, along with a new curved maxillary segmental distalizer stepped-up toward the gingiva, with Class II elastics. This produces a moment of force ($M_f = F \times d$) that is 50% closer to the CR of the maxillary dentition reducing tipping for bodily molar distalization. A mid-hook on the curved barre that is more proximal to the CR of the maxillary dentition additionally reduces direct canine over-extrusion. This also includes skeletal eruption of buccal segments that has been shown to significantly reduce muscle hyperactivity in deep overbite. Significant skeletal upper incisor intrusion of vertical maxillary excess with a severe gummy smile can be achieved using anterior TADs, elastics and new anterior aligner divot cut-outs in deep overbite. The aligner prescription of three differential supercorrections reduces refinements significantly in different complex malocclusions in practice. This shortens chairtime and treatment time that is noteworthy in this clear aligner update.

Orthodontic straightwire brackets have been reliable for three-dimensional finishing through a foundation of scientific physics-based biomechanics by Isaacson and Lindauer.⁴⁻⁶ However, they also require overcorrection compensations for their real limitations, and this is much higher for aligners. One example is in severe deep, overbite of 95%. There is a need to compensate for the general clenching and the hyperactive neuromusculature by applying Progressive Posterior Extrusion (PPE) for the deep curve of Spee³³

and compensating curve in the lower and upper archwires respectively with an average guide here of 150%, to 200% supercorrection for premolar extrusion that includes first molar extrusion with 7's present in the aligner technique.

Differential compensation for these complex malocclusions has reduced refinements significantly. To understand these supercorrections it is important for the orthodontist to first understand the geometry of bonds (attachments) completely by simply classifying them in order to be applied for virtual treatment planning in a practical, confident and effective manner.³⁴⁻³⁷ This is different from accepting, often on faith, the standard digital animation from remote software technicians. Rather, the orthodontist can reliably apply a depth of knowledge of geometry, biology and physics to aligners to prepare differential supercorrections.

Overcorrections or supercorrections are not new. During upper molar distalization a "Super Class I" is the goal to prevent mesial molar rebound, but applies to aligners at a significantly higher level in overcorrecting maxillary expansion, or "supra-eruptions", or overcorrection in severe rotations of round-shaped teeth.

Six basic resin bond shapes, preventing aligner gaps at U2 edges

It is important to keep bond design simple (Fig. 1A). One of the best ways to classify the resin bond shapes (handles, attachments, amplifiers) is to separate them into 6 geometries.

Beveled gingival bonds are commonly applied for tooth control in three-dimensions and allow for easier removal of the aligners. In severe open bites, protrusive elliptical bonds are staged on the lingual aspects of the 12 anterior teeth (β) unfilled and later punctured from the lingual to act as new Aligner Tongue Trainers.³⁸ They are reminders for the strong anterior tongue positioning, that occurs 800–1000 times/day, to retract from the anterior open bite (Fig. 16A). Other applications for unfilled elliptical bonds are for the correction of gummy smiles (Fig. 22A) and filled ellipticals can also be used on the buccal or lingual of short molars for added aligner retention or anchorage (Fig 9).

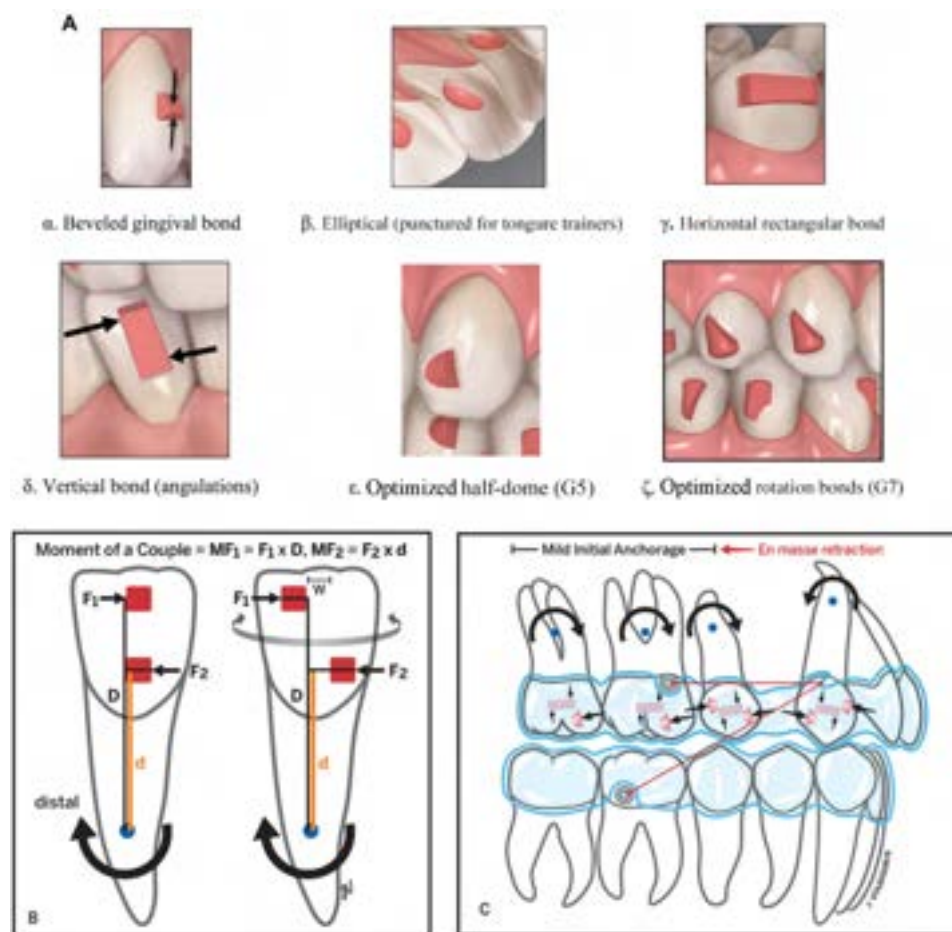


Fig. 1A-C. A. Six basic resin attachments or bonds (amplifiers) for aligners are one way to apply aligner forces (see Figs. 1D,E). B. This demonstrates the moment of a couple planned for distal root angulation of a LR2 to correct initial, mesial root tip toward the midline shown above. C. Extraction of the U4s with the application of optimized attachments, includes Invisalign® G5™ for the U6s, U7s, and G6™ attachments at the U5s and U3s prior to en masse incisor retraction with Class I and Class II elastics.

The six basic bonds are placed to allow the *aligner semi-elastic thermoplastic to push on a dental unit but they can also be used to produce relative retraction*. They can have different widths such as 2.5 mm on incisors or 4 mm for molars. These 6 attachments (Fig. 1A) and their permutations (Fig. 1B) can account for most of the bonds observed with aligners.

Fig. 1B shows a split vertical bond on a lower right lateral incisor (LR2) used to plan supercorrection of the root distally for anchorage and periodontal health because it is a challenge in adults with aligners. The vertical bond can be split by removing the mid-section for esthetics (compared to a one-piece vertical bond Figs. 6B, 20B,D). This bond mid-section is also largely non-functional biomechanically, and of little added patient comfort. Differential supercorrection for planned distal root

angulation is virtually programmed to 200% or +4°, to achieve the Alexander +2° angulation goal clinically. On the right, the same bond can be additionally spaced apart horizontally (w) for additional B-L rotation control. Note, the larger distance w of approximately 2 mm does not change the effectiveness of the planned distal root angulation since the forces are along parallel horizontal axes.

However, there is a highly effective clockwise moment for the distal root movement planned. The force F_1 can also be reduced automatically to balance with longer distance D from the assumed center of resistance (CR in blue) producing a moment of a couple (M_c), $MF_1 = F_1 \times D$, $MF_2 = F_2 \times d$. This contrasts with two equal and opposite forces exerted equidistant between the center of the *crown locally* that form a moment of a couple initially, if the CR

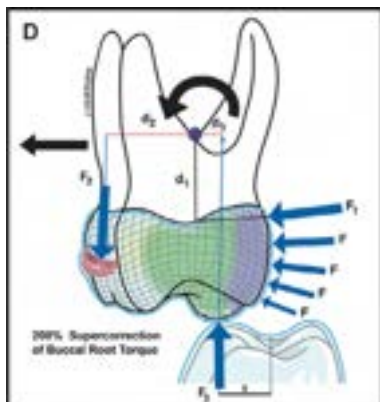


Fig. 1D. A 200% supercorrection of buccal root torque is prescribed virtually, to achieve clinically -7° continuous torque at U6s and U7s using new, large and wide optimized expansion support attachments (OXS here) for each molar (Invisalign®). They are placed for more effective and predictable molar torque using buccal and occlusal-directed force during expansion overcorrection (θ). Simultaneously new, multi-directional forces with different magnitudes are applied similar to a force-matrix enveloping the U7 (Invisalign® G8™) for maxillary expansion. Five or more different palatal forces, for example, are shown where the dominant F_1 is highest (used throughout here) and closer to the assumed CR to simplify the understanding of complex biomechanics. Higher forces are produced in the palatal purple area, moderate forces in green, and zero force in white on the buccal, like a heat-map. The dominant moment of a couple is $MF_2 = F_2 \times d_2$, $MF_3 = F_3 \times d_3$.

of the root encased in bone were not such dominant factors. Mild distal root angulation of the lower lateral incisors assists anchorage for Class II elastics by spreading the centers of resistance distally to prevent incisor relapse.

In addition, there are more sophisticated attachments available such as Invisalign® G5™ forming beveled half domes for anchorage and rotation (Fig. 1C). Esthetic G6™ optimized attachments use a moment of a couple (Mc) with two opposing forces along horizontal axes of the canine crown initially with the extraction of U4s to upright the roots for parallelism in retention (Fig. 1C). Simultaneous palatal, horizontal bonds (pink) on each posterior dental unit including the canines for greater root control use a moment of couple with two opposing forces along vertical axes (Fig. 1C).

In Stage 2 of extraction treatment progressive en masse retraction forces produce a relative pull-back of the incisors using the posteriors as anchorage. G7™ optimized rotational attachments (Fig. 1A) are also indicated for both rotation and directional movements.^{29,39,40} A power

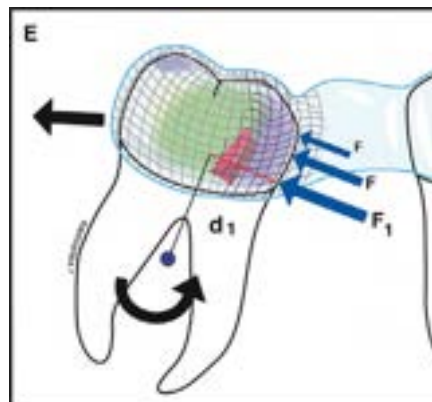


Fig. 1E. A tipped molar with space loss is shown with at least two aligner force methods 1) multi-directional forces of multiple magnitudes and 2) from force on a mesial beveled bond shown. This is a different example, in contrast to torque in Fig. 1D, because the aligner largely uses a dominant moment of force $MF_1 = F_1 \times d_1$ for molar uprighting and distalization compared to a moment of a couple. Initially tipped molars can also be observed with mesial rotation where a higher buccally-directed set of forces on the mesial-lingual molar surface can also be applied for early de-rotation (Figs. 4C,D).

ridge™ (Invisalign®) is another good tool for applying pressure points and an opposing pressure area for local anterior torque. Finally, new multi-directional force areas, having different magnitudes on individual dental units (Invisalign® G8™), are shown here in Figs. 1D, 1E.

Six Ways to Prevent Gaps between U2 Incisal Edge and Aligner for Ideal Tracking

Triangular, beveled attachments can also have two subclassifications, beveled gingival or beveled incisal Fig. 2. The beveled gingival bond specifically prevents one of the most common complications of aligner gaps at the upper lateral incisal edges.

Anatomically, both the root and crown of the upper lateral incisors (U2s) are the smallest in the upper arch, with a thin dentoalveolar housing. There are 6 reasons and associated methods to avoid the common complication of U2 gaps between the aligner and incisal edge. The clinician needs to choose 1) the proper bond geometry and biomechanics 2) without resin flash in treatment. Other reasons for gaps are 3) not enough space 4) tipping palatal displacements shown in Fig. 3 with 5) not enough alternating labial root torque and 6) general non-compliance with 23hrs/day wear with Clenchys™ or Chewies.™

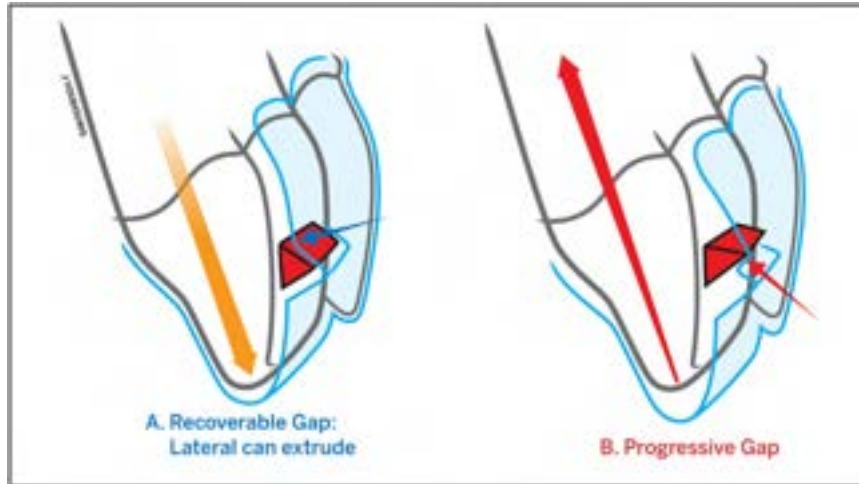


Fig. 2A-B. **A.** Beveled gingival bond captures ideally the U2 extrusion if gap appears since aligner contact (blue arrow) continues to extrude U2. **B.** The beveled incisal bond design, however, catches under the bond, wedges upward on the bond and intrudes the U2 resulting in a gap between U2 and aligner.

The same applies for U2 brackets that need to be inverted vertically for labial root torque when the root is palatally displaced. However, since mean accuracy for torque was found to be 42%,¹⁹ at least twice as much supercorrected torque, or 200% is the prescription here for aligners in stages (Fig. 7B). See JVoudouris Three Orders of Predictable Aligner Movement below.

Guide #1 Apply beveled gingival attachments regularly for U2 extrusion that prevents intrusion (Fig. 2A), not beveled incisal bonds (Fig. 2B).

Guide #2 Program a) enough space to b) permit the palatally-positioned U2 to move bodily (and re-extrude).

This prevents leaving the U2 behind, including any incisal edge gap. Emphasis is on three patient keys: 1) aligners need to be fully seated 23 hrs/day 2) aligners are changed every (q) 7 days on average 3) aligner appointment intervals are q 6-12 weeks to maximize patient control and efficiency. The velocity of movement on the most complicated tooth is usually not changed at .25mm/aligner, 2°/rotation or 1° torque.

Guide #3: Avoid labial tipping alone of palatally displaced U2s during alignment (Fig. 3). It causes a natural relative intrusion and requires labial beveled gingival, and often palatal horizontal bonds on

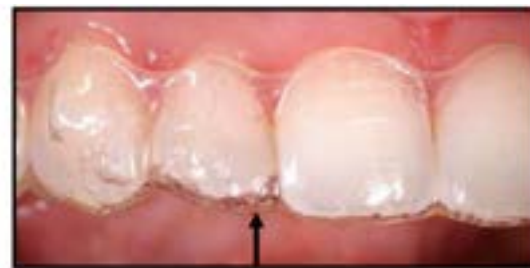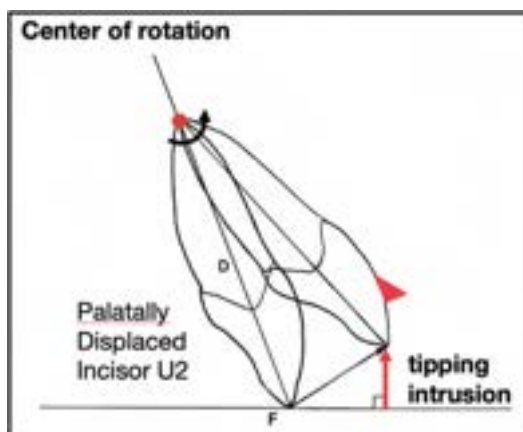


Fig. 3. Tipping the lateral incisor labially uses the center of rotation (not CR). This produces a moment of a force $Mf = F \times D$, and relative *intrusion* (red arrow) away from the aligner that forms a gap. Conversely, when a proclined U2 is retracted, it extrudes into the aligner that is favorable in terms of preventing a gap (see Fig. 19H).

U2 for labial root torque. This is because tipping causes the U2 to swing upward from the center of rotation⁶ and away from the aligner resulting in a gap called tipping intrusion (Fig. 3)

Guide #4 Effective palatal root torque of U1s can cause extrusion of the U2s in Class II div 1 and div 2 where smaller U2s need labial, beveled gingival bonds to maintain U2 position and torque (Figs. 1A, 2A, 7B). See tracking complications and solutions below.

Aligner interdisciplinary treatment: molar intrusion and uprighting

Guide #5 Anterior gingival recession can be prevented, reduced or often reversed mildly, by not moving the periodontally involved teeth until space has been made for retraction. In addition, 200% lingual root torque on L3s can be applied to improve minimally attached gingiva.¹⁹

Guide #6 Supra-erupted molars due to the loss of the opposing antagonists can be intruded without bonds 110% because in these localized cases, molar intrusion is one of the easiest movements for aligners (Fig. 4). On the teeth adjacent to the molar being intruded, wide 4 mm horizontal beveled occlusal bonds are placed for vertical anchorage in the buccal segments and for aligner retention (Fig. 4A, F).

Similarly, worn and over-erupted short molar crowns can also be intruded at minimum 3-4mm, prior to prosthodontic treatment to restore them with higher crowns.

Guide #7 Tipped molars can be uprighted with buccal, beveled bonds on the mesial of the tipped molar for ideal control because molar tipping is another relatively easy aligner movement (Fig. 4). Since aligners cover the molars for distal intrusion, molar uprighting may also be accomplished without bonds. Once again, it is critical that the scan include the distal of the most distally tipped molar for uprighting control, and the patient locks the aligner under the bond to avoid more severe tipping. Typical mesial bone loss is improved with molar uprighting (Fig. 4C,E).

Guide #8 Do not place pontics at the missing lower molar to be able to push on the entire mesial surface of the tipped molar with maximum multi-directional force.

Molar intrusion and molar uprighting are significantly improved with aligners. They cover the denotation naturally that facilitates intrusion and are an improvement compared to bracket uprighting with long archwires and tip-back bends. This is because

wires can be deformed by chewing, pulled-out of the tipped molars, result in wire-end protrusions and soft tissue lacerations (Fig. 4A-F).

Aligner De-rotation 110% and angulation 200% supercorrection

Guide #9 Compensate with 110% de-rotation for severe rotations $\geq 15\%$ generally. They are often resistant as in long-rooted L3s, and certainly with buckled, V-shaped rotations of U1s or L1s (Fig. 5A,B).³⁶

Guide #10 It is easier to step-back the patient and not use 1-2 supercorrected aligners at the end of treatment, rather than re-scan and have the patient wait for refinements.

Guide #11 Two sets of bonds in a T-design pattern on tipped and converging L2 roots are used with 4 forces/L2 to supercorrect 200% and virtually plan distal angulation of 4° (Fig. 6A,B).⁴¹ A wide, lingual rectangular bond is over-tipped to the midline (Fig. 6A) with a long, labial vertical bond on the straighter, longer labial surface (Fig. 6B) and IPR.^{42,43} In retention this provides a trapezoidal geometry of the diverging four incisor roots in Fig. 6B to prevent relapse for extremely complex angulation (that is similar to torque and extrusion).

Torque incisors with 200% supercorrection, and with Andrew's counter-wagonwheel angulation

Anterior and posterior torque,⁴⁴ and incisor or molar extrusion, with root angulation can be complex movements with aligners. This depends on severity and where they are located. The etiology of malocclusion is often a complex combination of genetic and environmental factors, without a one-cause-effect. When there is a tag-team battle in the clinical arena between etiology-muscles, and bone-teeth with aligners, etiology-muscles win.³⁸ Molar extrusion can be challenging with clenching and muscle hyperactivity given that aligners cover the occlusion. Aligner forces reduce over 1-3 days with stress relaxation during both molar extrusion, and torque that also generally requires 200% supercorrection to be expressed (Fig. 14G, L)

Guide #12 In Class II division 1 deep bite malocclusion Stage 1 is simultaneous intrusion with 200% torque supercorrection to place U1 roots into a wider trough of bone (Fig. 7A, B), followed by Stage 2 retraction. For en masse palatal root torque, labial and palatal beveled gingival bonds are used to produce an effective moment of a couple Mc (Fig. 7B). The Stage 1

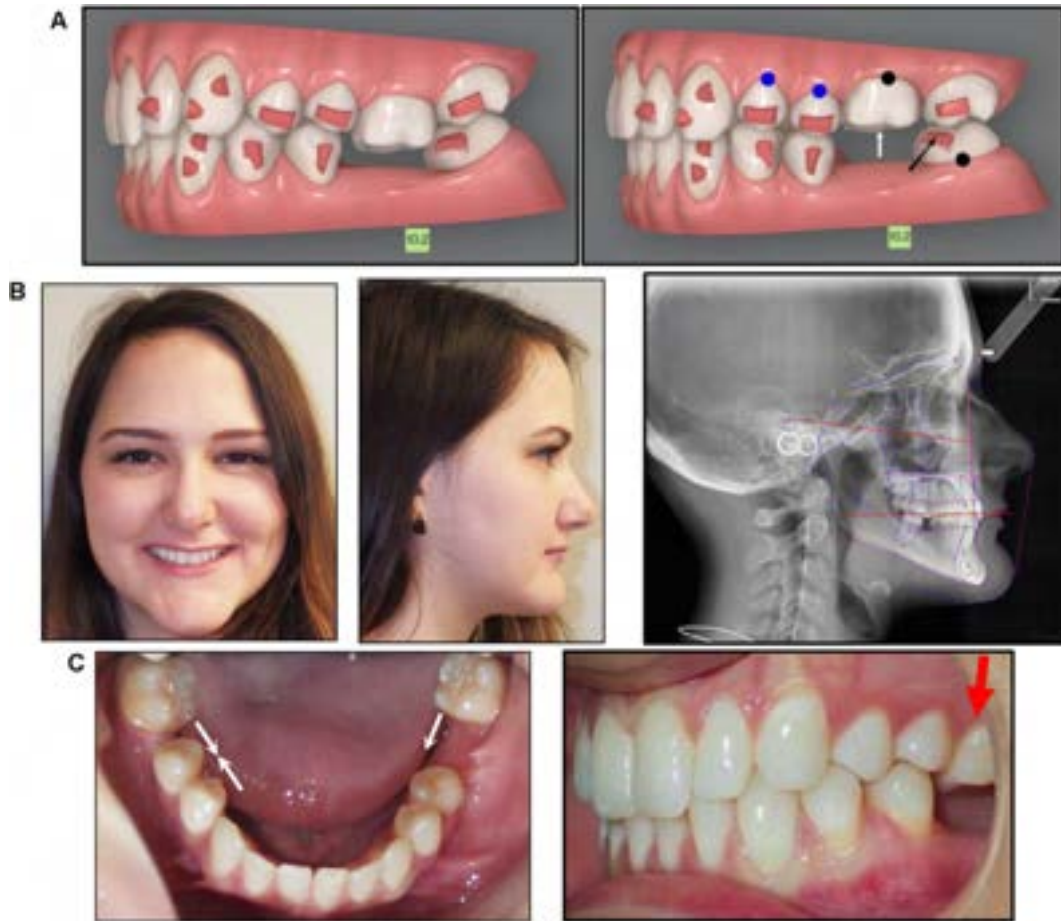


Fig. 4A-C. A. Molar supra-eruption is on the left, with 110% intrusion and lower molar uprighting on the right using a beveled mesial bond (black arrow). B. Patient 21 years of age has severe second molar tipping due to missing lower first molars, with extrusion of upper first molars. The overbite is deep, and premolars severely rotated with drifting into extraction spaces. FMA = 21° is low angle with muscle hyperactivity, including normal limits for IMPA, U1 to NA. C. The upper first molars are extruded 3mm vertically into the extraction sites of the lower first molars. The lower left and right second molars demonstrate severe mesioangular tipping of 60° with mesiolingual rotation.

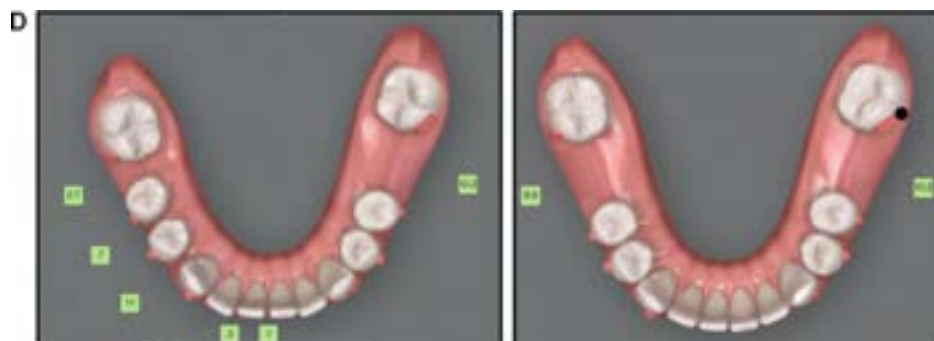


Fig. 4D. Correction of initial mesial rotation of LL7, and 7.2 mm of space opening at LR6 is shown.

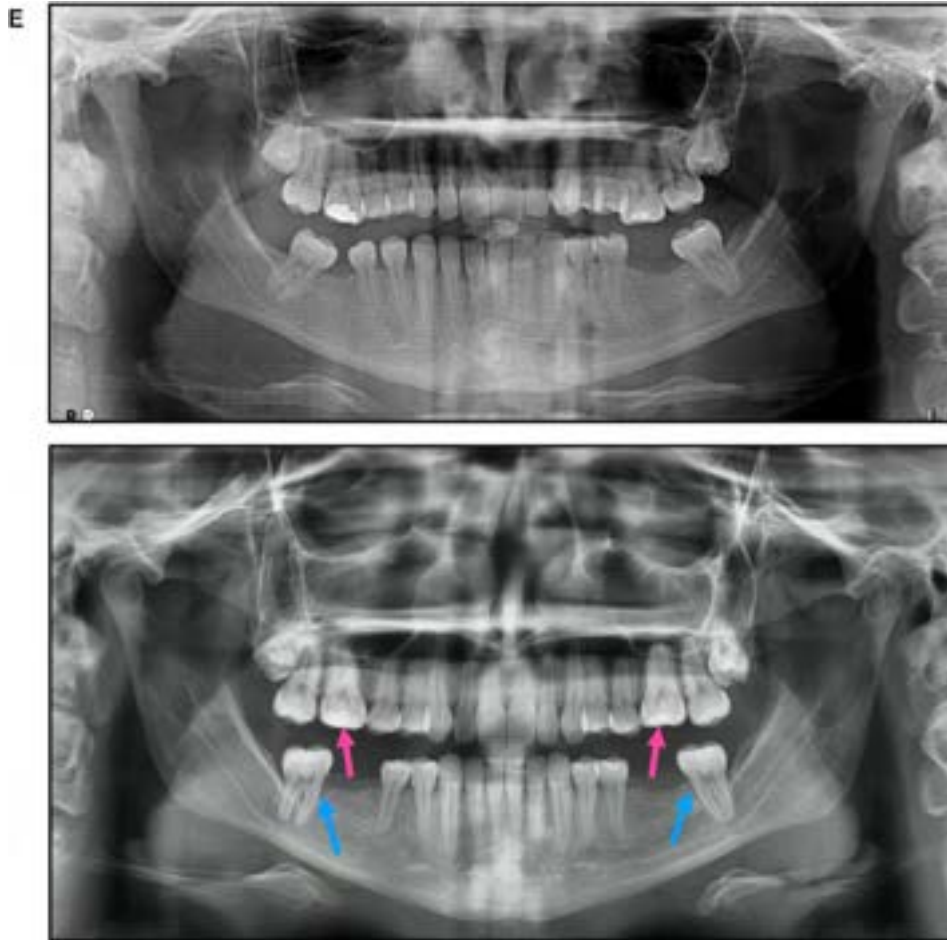


Fig. 4E-F. E. Supercorrection of 110% has produced highly effective aligner over-intrusion of the upper first molars and the full 60° uprighting of the lower second molars shown in the bottom panorex. This is following a total of 27 initial stage aligners, and another 33 aligners in refinement changed every 7 days. F. The deep overbite has been corrected with the lower molar uprighting and with mild lower incisor intrusion. Upper and lower 1 mm thick aligners (spring retainers, or fixed lower 3-3 retainers) are used prior to prosthodontic replacement of the lower first molars. This demonstrates the high effectiveness of aligner intrusion due to the occlusal and buccolingual coverage without an U6 molar attachment. Similarly in the lower arch the grip of the aligner plastic around the L7s for uprighting with multiple multi-directional forces that helps intrude the distal ends of the L7s is equally effective with aligners. Compared to less accessible L7 brackets in adults where wire tip-back bends can extrude the molar and cause significant mobility, this is controlled by mild intrusion of full occlusal aligner coverage and as an occlusal guard for the molar. Five dental surfaces are enveloped by aligners for controlled uprighting.

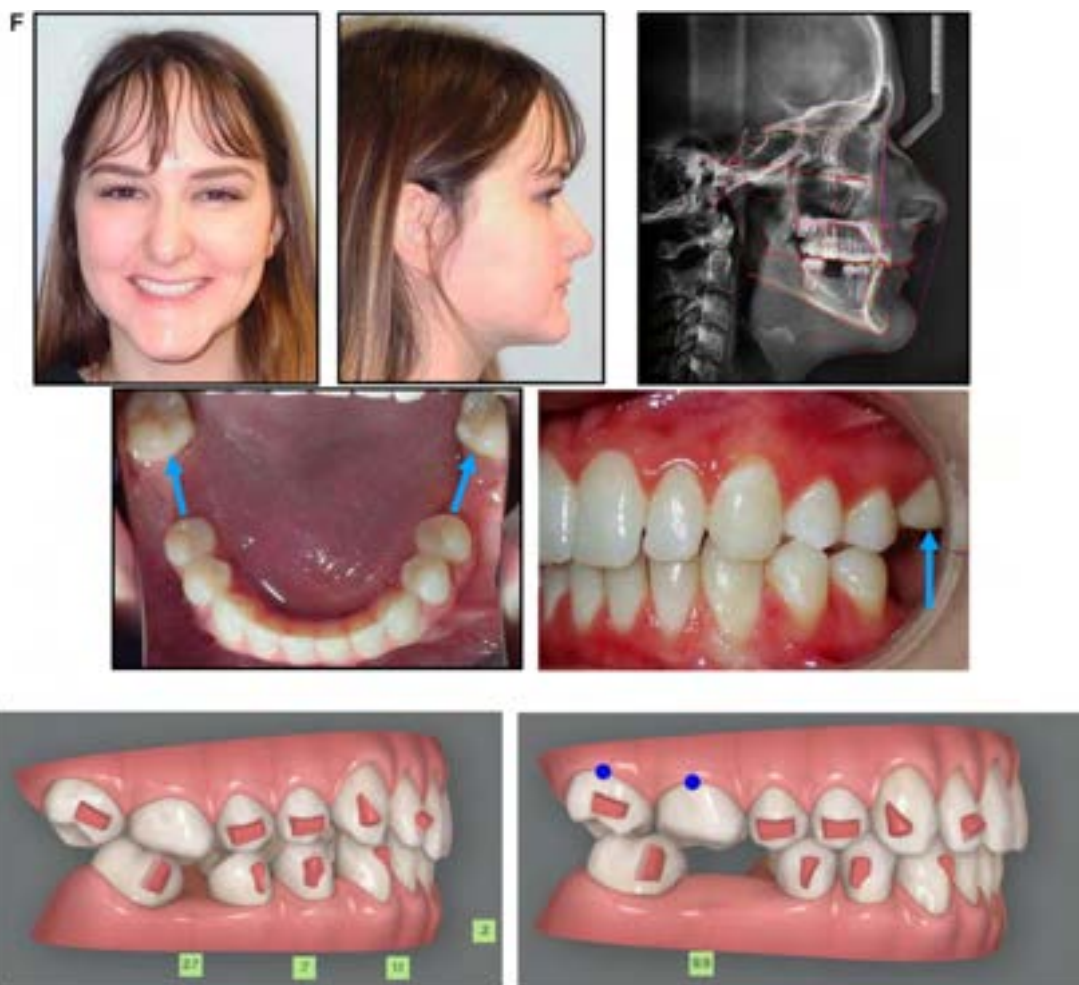


Fig. 4F. Continued

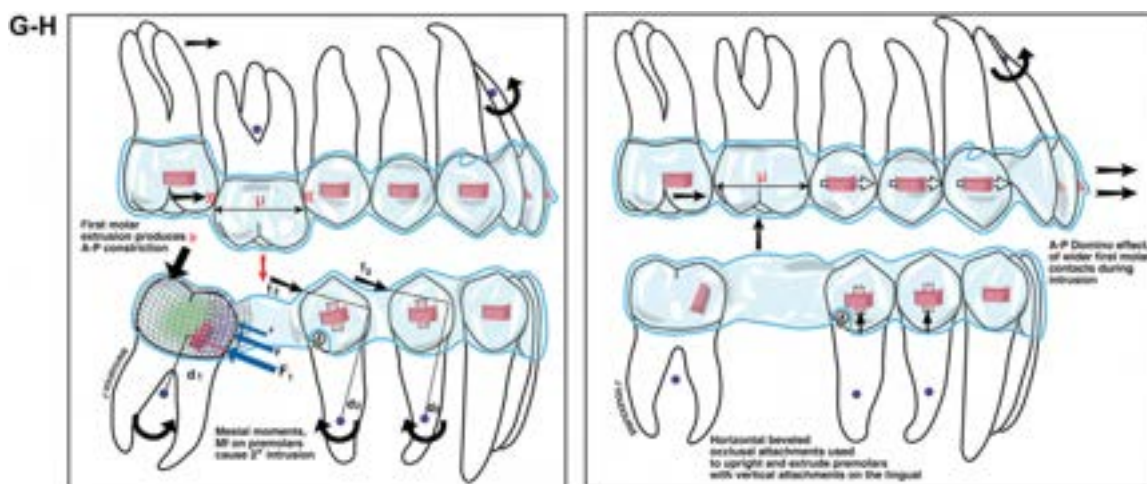


Fig. 4G-H. **G.** Separately, a U6 is supra-erupted with the narrower gingival part of crown taking up less space (red double arrows) resulting in the mesial movement of U7. In **H** when the molar is intruded the wider middle contact length μ , requires more space otherwise it wedges upward, that tends to produce a succession of mesial forces that may result in a Class II canine relationship. This is easily controlled with Class II elastics starting at the L5s. When 1) the L7 is uprighted distally 2) the L4,5 are moved mesially with a reciprocal intrusive force on the L4, 5 with aligners. T-design of the more vertical lingual (dashed lines), and small horizontal buccal attachments as shown alternatively, can be used (4 forces in 2 planes) to prevent reciprocal intrusion on L4, 5. Overall dominant moments of forces are simplified here where there are multiple force magnitudes being applied to the tipped L7 (including intrusion) that change with each aligner including on the attachment.

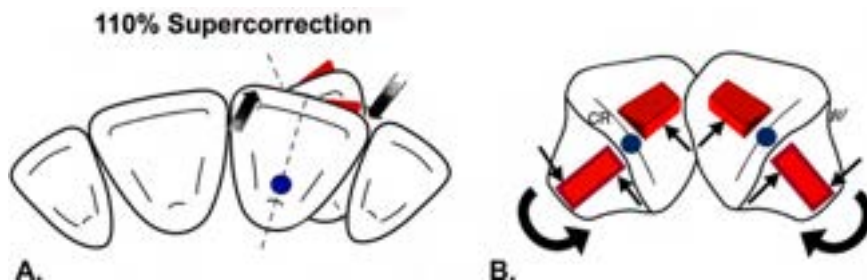


Fig. 5A-B. A. Rotation supercorrection of 110% is programmed to anticipate aligner force loss over 1-3 days and dental lag. B. V-shaped L1 crowding is resistant, where beveled bonds are used on labial, and vertical bonds on lingual. Space is opened first for L1 crowns to move distally, and roots to rotate around the Center of Resistance (CR in blue, one-third from the root apex), with the required 110% supercorrection of these severe and highly complex rotations for finishing (A). Lingual cut-outs and bondable buttons may also be employed with elastic chain for reciprocal forces.

*intrusion-torque prevents root resorption against the labial cortical plate prior to retraction.*¹⁵

Guide #13 In Class II div 2 malocclusion Stage 1 is U1s are uprighted mildly (proclined), then in Stage 2 intruded with palatal root torque, and Stage 3 retracted with the U2s.

Guide #14 Stage 1 intrusion-palatal root torque uses labial, beveled gingival bonds on U1s, U2s, or vertical bonds on U2s to assure the software program in Stage 2 angulates the roots distally (Fig. 8A,B).

The rationale is U1 and U2 palatal root torque will cause the roots to also naturally converge to the midline when viewed from above the roots. These vertical bonds on U2s counter Andrew's converging wagonwheel effect observed with anterior palatal root torque. The two movements are staged, and not completed simultaneously to maintain root integrity demonstrated with aligners⁴⁵⁻⁴⁷ since Weinstein has shown biological tooth movement can occur with *1gm of light, continuous force*.⁴⁸

Vertical bonds at U2s use a moment of a couple along horizontal axes for angulation, similar to rotating a steering wheel using two opposing hand forces in opposite directions equidistant from a center point.

Anchorage of aligner over bonds and aligner removal instructions

Guide #15 Patients are instructed to "press and snap over bonds similar to snapping on a baby bottle cap" to enable lifting the bottle from the cap. For both ease of removal and to prevent aligner breakage, the patient is instructed to remove the aligner from the smooth, distal-lingual ends first (may use Pul™ hook). The aligner ends act as free cantilevers to unlock and remove the aligner evenly on both sides, when possible, to prevent aligner breakage.

In patients with short crowns horizontal bonds need to be applied at the last molars on the

mesio Buccal cusps for added retention, and for anchorage during supercorrection of rotations greater than or equal to 15° (Fig 9A,B).

Youth clear molar distalizer with aligner anchorage, Class II elastics for mild dentofacial orthopedic effects

Skeletal Class II malocclusions with deep overbite combined with overjet^{49,50} are common and often have a counterclockwise mandibular growth direction⁵¹ with clenching and muscle hyperactivity.

*Guide #16 For maxillary segmental distalization the first step is "Vertical Molar Uncoupling" using anterior bite ramps⁵² ranging from all upper anterior locations, upper 3 to 3 (Fig. 10) and second, crossbite correction. A new Clear JVBarre® 4D™ has been clinically tested for 2 years with an average length of 25 mm measured from the upper first molar buccal groove to center of the canine crown.*⁵³

Guide #17 The third step is "Horizontal distalization" produced with the Clear JVBarre® 4D™ force. It has a mid-hook on the curved barre for an elastic force of 1/8", 6.5 oz when stretched about 2-3 times the lumen size. The JVB is worn for 3-4 months in 1/2 cusp Class II, and 4-6 months for a full-step Class II, with the end goal a 110% Super Class I molar relationship (Fig. 11A, B).

Guide #18 Scientific investigations have also shown that Class II elastics with maxillary segmental distalizers produce some skeletal effects including maxillary restriction⁵⁴ verifying that the effects of Class II elastics are often trivialized.⁵⁵ The Adams et al study has further demonstrated histologically that extended Class II elastics are associated with new bone formation at the condyle,⁵⁶ including the glenoid fossa (C-GF)^{57,58} similar to functional appliances studied with MRI in humans.⁵⁹ Condylar endochondral ossification (C) and glenoid fossa appositional bone

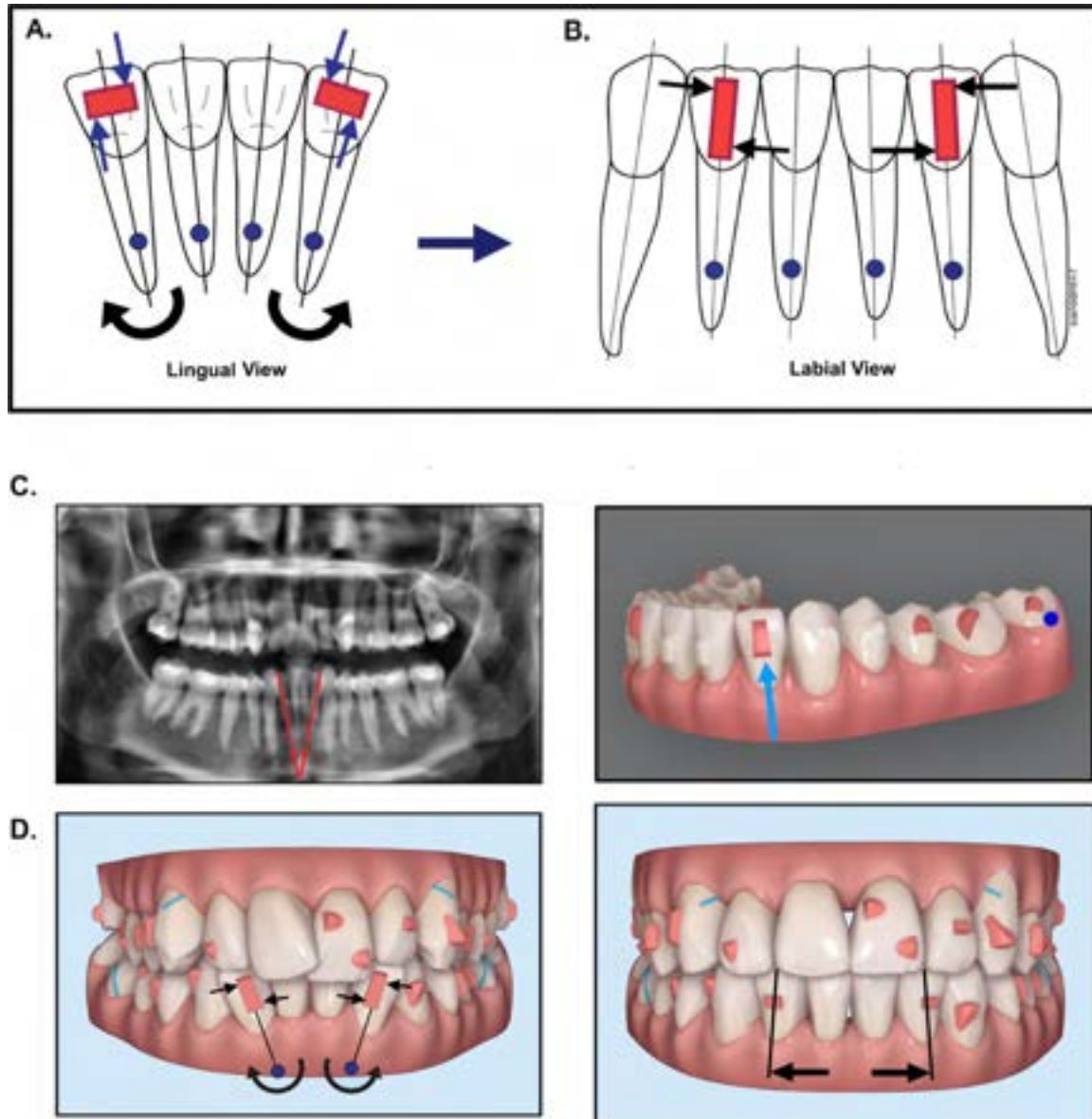


Fig. 6A-D. **A.** A lingual view of root convergence shows for each L2 a horizontal bond with 2 opposing forces along the vertical plane for a moment of a couple (M_{c1}) angulating the L2 roots distally with 200% supercorrection and IPR.^{42,43} **B.** The labial view shows an additional vertical bond with 2 labial forces along the horizontal plane producing a second M_{c2} . A T-Design pattern is formed with the horizontal bond and vertical bond for each L2. **C.** These 4 different forces in total, use 2 moments of couples, along 2 planes on each L2 and are indicated for highly effective correction of severe root convergence shown in the panorex of an adult patient with osteoporosis. Horizontal bonds are selected on the lower lingual for tongue comfort, and vertical bonds on the lower labial here because they are generally covered for esthetics by the lower lip (see inversion of esthetic T-Design for upper incisors in Figs. 20A,B). Extraction of a periodontally sound lower incisor may compromise anterior guidance and produce greater overjet. **D.** shows the initial, and final 200% supercorrection of 4° angulation of the L2s in the aligner to achieve 2° clinically and to prevent root re-convergence. Distal angulation of all 4 lower incisors also spreads the CRs laterally that reduces en mass proclination of the converging lower incisors with Class II elastics. The reason is converging incisor roots pivot more readily forward, with Class II elastics from the skeletal midline region, and act similar to a single center of resistance of a Japanese fan or wagonwheel.

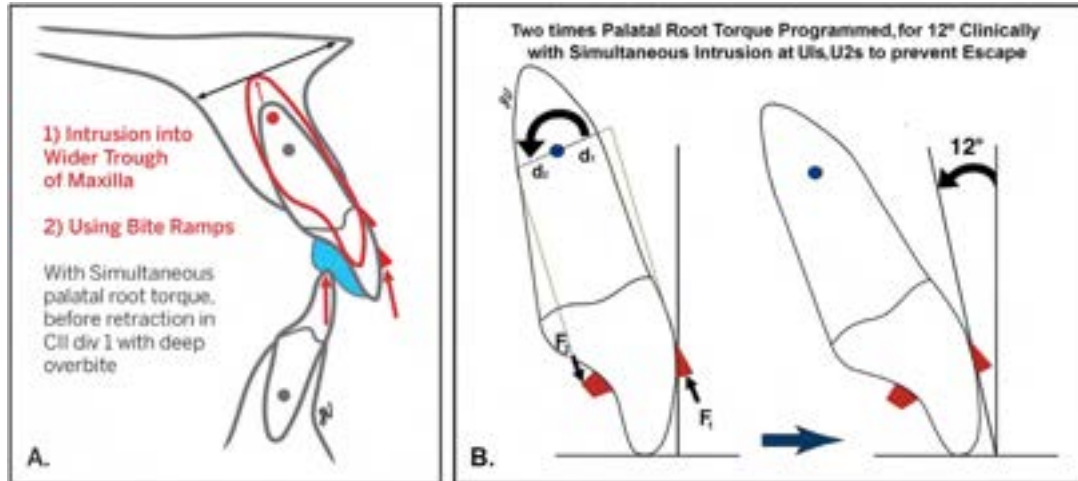


Fig. 7A-B. A. Simultaneous aligner biomechanics in Class II division 1 with deep overbite includes Stage 1 intrusion *with* B, an average 200% en masse palatal root torque of U1s, U2s prior to Stage 2, retraction. General incisor intrusion is facilitated with palatal bite ramps (A). Note, labial and palatal beveled gingival bonds (B).

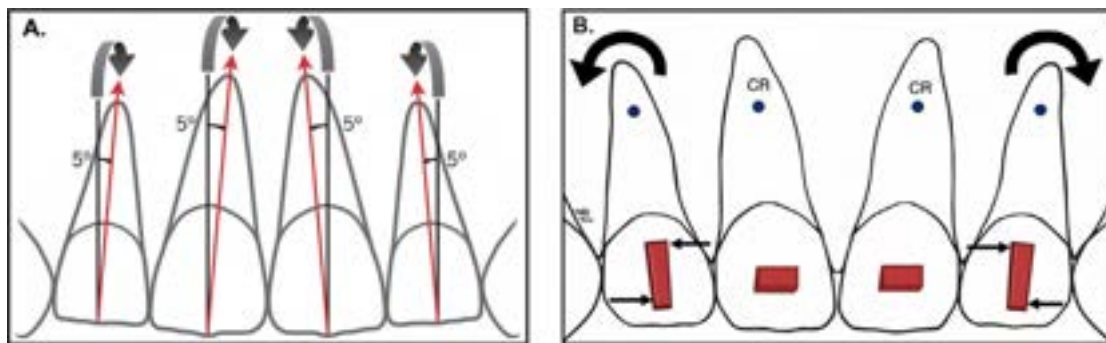


Fig. 8. Near the mid-treatment following anterior intrusion-palatal root torque, Stage 2 begins with vertical bonds on U2s to angulate roots distally using opposing forces for moments of a couple. U2 root angulation shown near the Center of Resistance (CR), located about 1/3 from the apex, prevents undesirable convergence of the U2 roots for the anti-wagonwheel effect. *Torque first, angulation second is staged to prevent root resorption.*

formation (GF) are a result of 1) physiologic displacement of the condyle 2) stretched retrodiskal tissues and 3) transduction of forces within the TMJ.⁶⁰ Although a large portion of the C-GF changes may relapse without retention the remaining C-GF modifications are not found to be zero⁶¹⁻⁶² and are only 2 components of the total 12 contributions to dentofacial Class II correction (Fig. 25A,B). The objective is to remove restrictions, such as viscoelastic lip entrapment, not for extra growth above the average for controls but rather, to facilitate full expression of individual mandibular growth (Fig. 13F,G).

In non-compliant patients, fixed, thicker Class II springs (DynaFlex® CS-2000™) can also be locked by crimping onto both the JVB mid-hook and the L6 band hook, with lower

self-ligating brackets. Moderate diameter TADs or ideally surgical infrazygomatic L-shaped mini-plates with loop hooks (Figs 19D,H) may also be applied above the U6s for elastic chain or Class I NiTi coil spring to the JVB mid-hook to distalize the U6s (Fig. 12).

The JVBarre® 4D™ mid-hook on the curved barre also controls canine over-extrusion. This places the moderate 1/8", 6.5 oz elastic force biomechanically closer to the center of resistance (CR, blue) of the U6 in Fig. 10 for more bodily molar movement with a curved barre that reduces biomechanical molar tipping.

The key principle is to upright the molar roots during Super Class I molar distalization. Molar

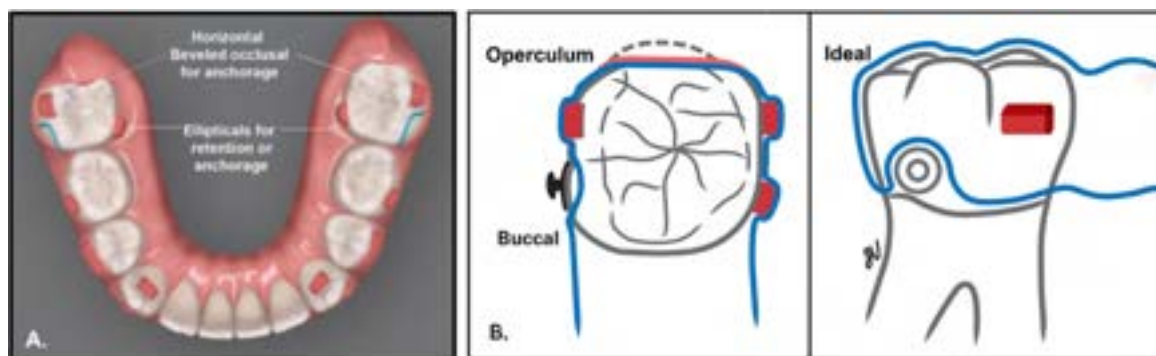


Fig. 9A-B. A. Since anchorage for deep bites has been a low priority for software, lingual horizontal or elliptical bonds are placed on the lower molars for greater retention, tongue comfort, and particularly when there are short crowns that may also have severe posterior attrition. They provide added anchorage with the buccal horizontal beveled occlusal bonds on L6s as shown. A key is to scan distal of the first or second molars completely when applying Class II elastics for four objectives, 1) to maintain mandibular arch anchorage in **B 2)** prevent lower incisor proclination 3) prevent aligner escape off the arch and 4) prevent lower molar mesial rotation by pulling from distobuccal with heavy Class II elastics. Kaplan hooks (Fig 4G,H, 24A) allow multiple elastics to be placed (e.g. reverse-pull headgear with Class III elastics) and can be more comfortable.

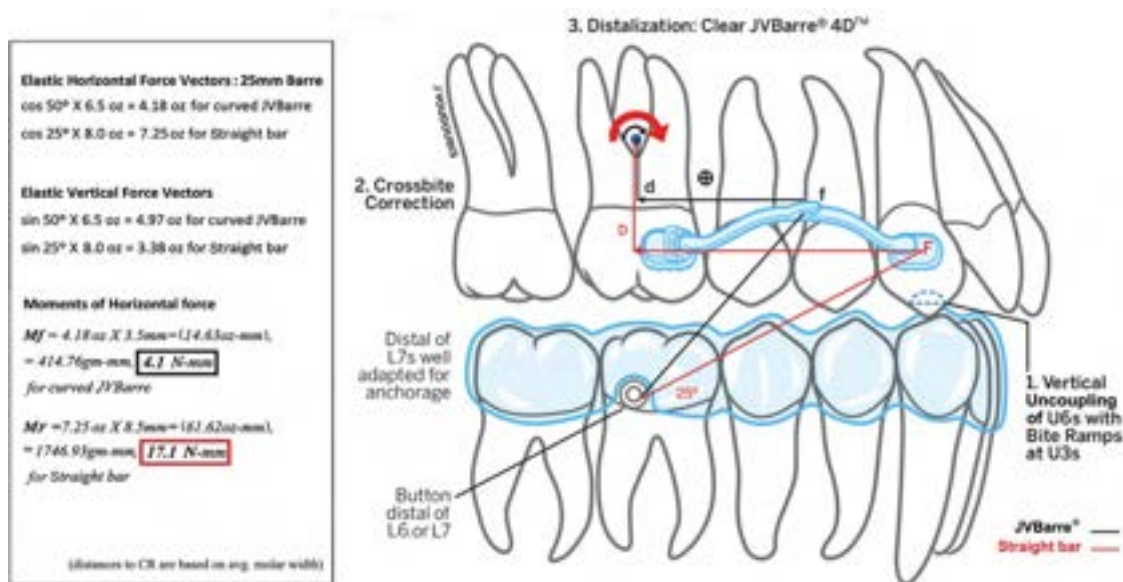


Fig. 10. Stage 1 of upper molar distalization in Class II division 1 severe overjet and deep overbite uses a Vertical, Transverse, Sagittal (VTS) Technique initiated ideally when the lower incisors are upright over basal bone.* The first step is *vertical* molar uncoupling with bite ramps U2-U2, or at U3s (dotted) when the overjet is severe that reduce occlusal resistance to facilitate molar distalization. Simultaneous Step 2 is crossbite correction to eliminate *transverse* molar interferences. This is followed by Step 3 *sagittal* molar distalization with the curved barre design for the elastic force to be 50% closer to the CR of U6 for more bodily movement demonstrated in Figs. 13C,D,E (and in Fig. 12 using the biomechanically appropriate CR of the Dentition). The new Clear JVBarre® 4D™ is shown with a lower, 1mm thick passive Vivera™ (or Essix™) clear aligner, to start this esthetic stage immediately when motivation is highest with elastics. *This makes use of lower dentoalveolar calcification and mineralization for anchorage without initial alignment.* Bondable buttons or Kaplan hooks are placed on the distal of the L6s that locks-in the elastics, (or ideally mesial of L7s for greater elastic activation Figs. 11A,B). The angle of the elastic to the occlusal plane for the average 25 mm long JVBarre is 50° compared to elastic angulation to a straight bar of 25° for force calculations shown, and finite element analysis. *Following Stage 1 if the lower incisors are *not over basal bone and proclined* (IMPA $\geq 93^\circ$) a cornerstone, in Stage 2 non-extraction finishing, is to plan the lower active aligners with moderate lower incisor IPR for retraction, intrusion and clinically, labial root torque of -6° for stability. Following lower incisor uprighting, lower Progressive Posterior Extrusion (PPE) is also programmed to alter the curvature of the aligners and complete the correction of the deep curve of Spee (see Fig 14 A-L). Simultaneously, in Stage 2 the upper finishing aligners continue with the bite ramps and lighter 3/16", 4.5oz, Class II elastics.

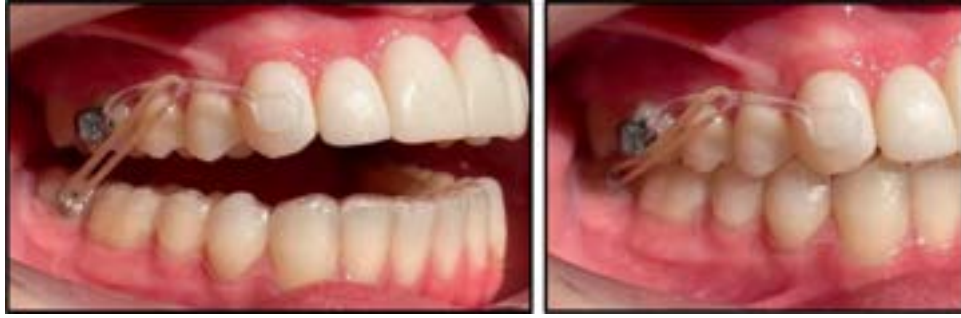

Fig. 11A-B. A. An esthetic clear system combines the clear JVBarre[®] 4D[™] with the clear lower aligner and Class II elastics 1/8", 6.5 oz. B. The JVB technique produces an overcorrected Super Class I occlusion (with the immediate placement of elastics initially when *compliance is highest*). Moderate 6.5 oz elastic grips firmly into mid-hook and L7 button during closure to act as a mandibular advancer (MA). The distal of the L7 molar is covered by thicker 1mm aligner (versus .75mm active) for maximum anchorage using the entire calcified lower dental arch early as anchorage. In Stage 2, full upper and lower alignment includes lower incisor uprighting and Class II elastics.

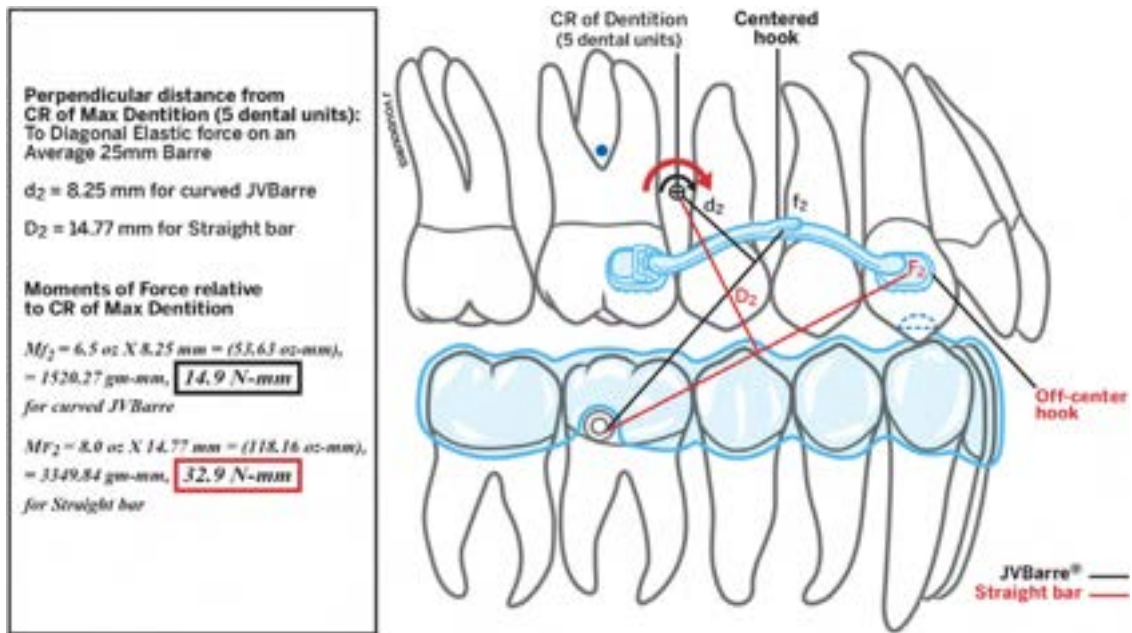


Fig. 12. Elastic force on the mid-hook of the curved JVBarre[®] 4D[™] is also closer to the CR of the dentition (5 dental units), with a centered indirect moment of force away from canine. An average 25 mm length of the curved barre from central groove of the U6 to center of U3 keeps indirect extrusive forces centered to prevent canine extrusion. A straight bar in comparison has an anterior off-center direct moment of force that is more than double affecting canine extrusion. Measurements in Newtons are the standard international unit of force in physics.

brackets with 14° of anti-rotation use only a fraction of the necessary rotation. A dental scan is taken after the removal of the JVB[®] 4D[™] and on the same day a 1 mm thick clear temporary retainer is made in the office and inserted immediately. This prevents any molar movement until the Stage 2 upper and lower aligners are ready within approximately

four weeks. A removable thick anterior bite plane is used for long-term retention.

Guide #19 The same Clear JVB[®] 4D[™] can be used from U4-7. In addition, a shorter set from U4-6 can be employed for adult esthetics. In children that are older than 13 years of age, it is key to check the position of U8s for impaction and the possible need for enucleation prior to initiating U6-U7

distalization. Sufficient U6, U7 rotation and distalization with aligners alone have been found to be predictable⁶³ but require greater time of 21 months compared to the JVB of 6 months (Fig. 13H) for all U7s and U6s to reach a 110%

Super Class I occlusion. Stage 1 maxillary segmental distalization with a lower aligner and Class II elastics that successively pushes the U6s mainly against the U7s requires usually less than 4-6 months of treatment, prior to Stage 2.

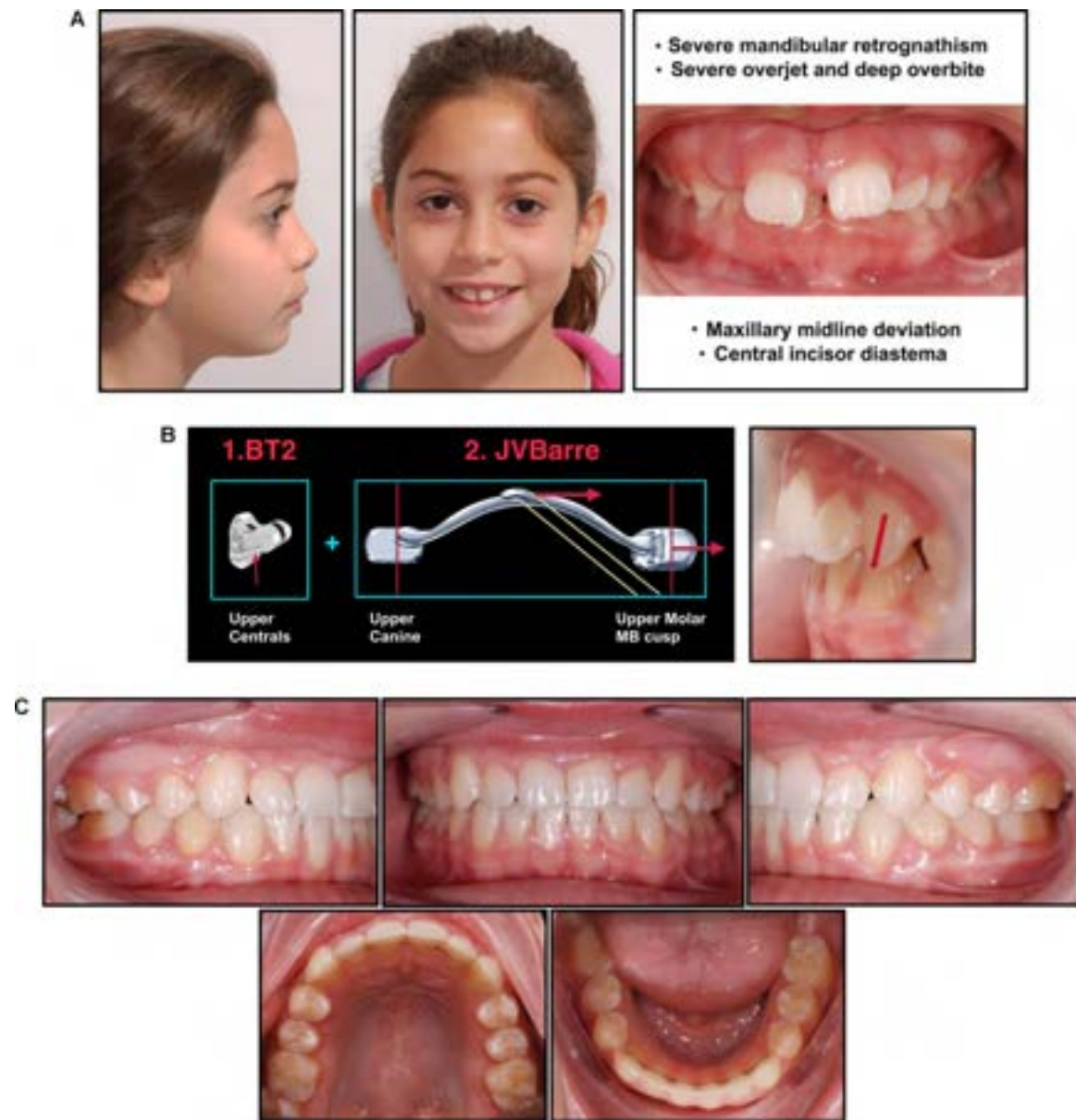


Fig. 13A-C. A. Youth treatment in three short stages is shown for an 8-year-old with the chief concern for smile esthetics including an initial overjet of 8 mm complicated by 100% overbite and skeletal mandibular retrognathism. In the initial stage, all incisors are treated with intrusion and the upper incisors retracted to a 4mm overjet to prevent trauma with deep overbite correction of 25% while coordinating the midline for esthetics in 8 months. B. Stage 2 begins with the eruption of the permanent dentition at age 12.5 years to correct the Class II molar and canine relationship (red arrow). VTS protocol uses 1) bite ramps (or BT2s) at the incisors to open the *vertical* dimension for less resistance during molar distalization 2) *transverse* crossbite correction 3) a new *sagittal* maxillary segmental distalizer JVB[®] 4D[™] is applied with 1/8", 6.5oz. Class II elastics for 6 months. A lower 1mm thick aligner is also applied for anchorage to achieve and maintain in C, a 110% Super Class I molar relationship after Stage 3 finishing. The distalizer also preserves facial esthetics by preventing extraction of the U4s.

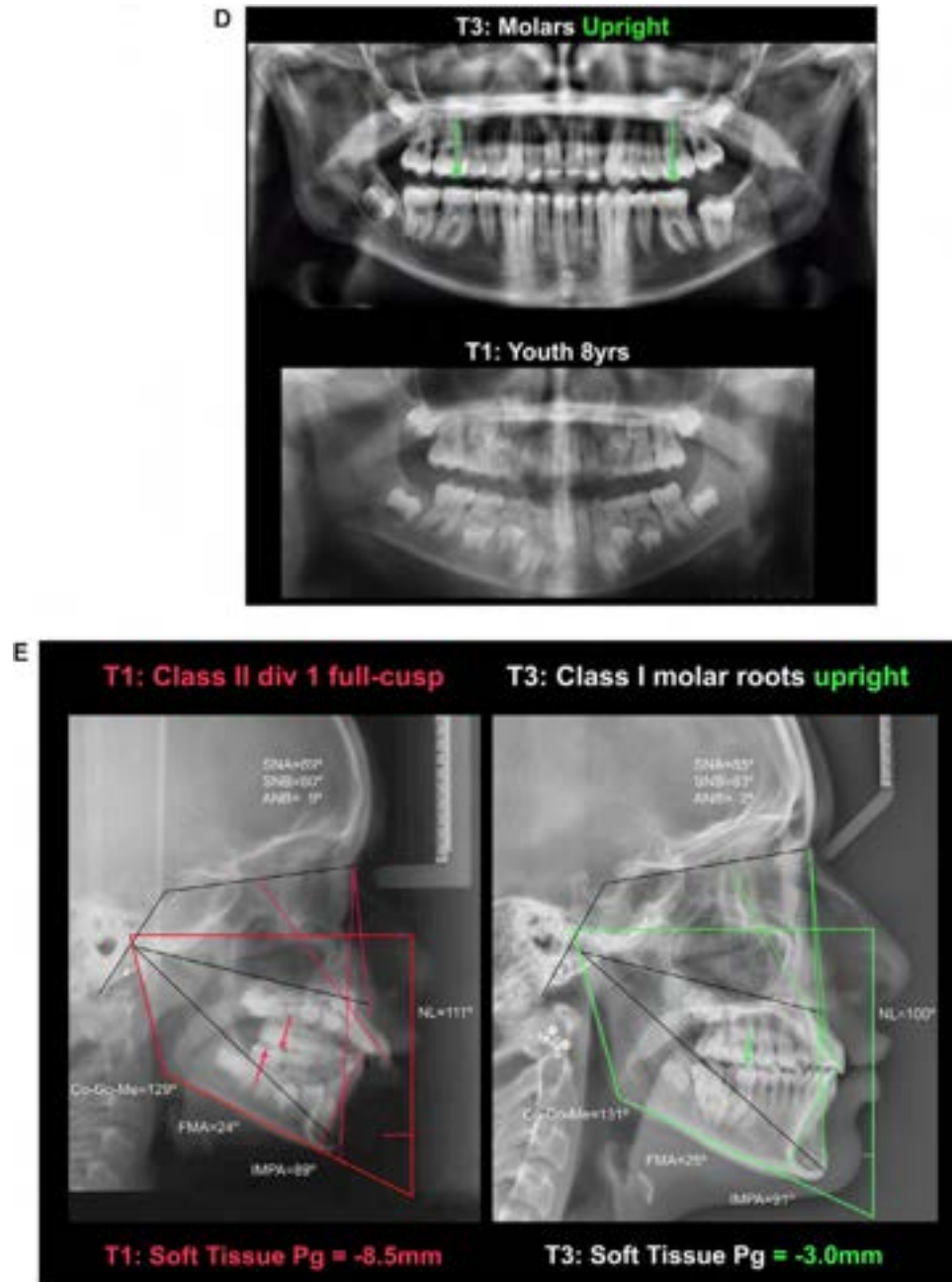


Fig. 13D-E. **D.** Note, a temporary upper aligner with U3 cut-outs is required for 1 month to maintain the molar supercorrection during the processing of the Stage 3 final aligners for medium 3/16", 4.5 oz Class II elastics that follows immediately for finishing shown in the T3 panorex. It also demonstrates the *upright positions of the upper first molars by using a moment of force that is closer to the centers of resistance of the upper first molar, and dentition.* **E.** Good dentofacial orthopedic changes are shown cephalometrically with a reduction in the retrognathic soft tissue Pg-point from -8.5mm initially to -3.0mm (avg. -2mm) in T3. ST-Pg is measured consistently since it is one of the most visible landmarks esthetically and measured from a perpendicular line to Frankfort horizontal, passing through soft tissue subnasale (ST-Sn) in a Tetrahedron Analysis (Voudouris and Voudouris, 2019). The ANB is reduced from 9° to 2° with the improved mandibular position. The lower incisor positions were relatively well maintained over basal bone for retention. Aligner coverage has the desirable tendency to restrict U4 to 7 eruption required in Class II correction. The principle of applying *differential extrusion*, for each of the upper and lower arches, makes use of upward and *forward* extrusion of the lower premolars and first molars (with L7s as anchorage) from the angled lower border of the mandible with lower Progressive Posterior Eruption (Fig.14 A-J). Simultaneously, upper buccal segment growth in a downward and forward direction is also restricted by the upper aligner that further assists Class II treatment. *Segmental upper molar rotation with upper and lower differential extrusion* are applied together to facilitate effective Class II correction.

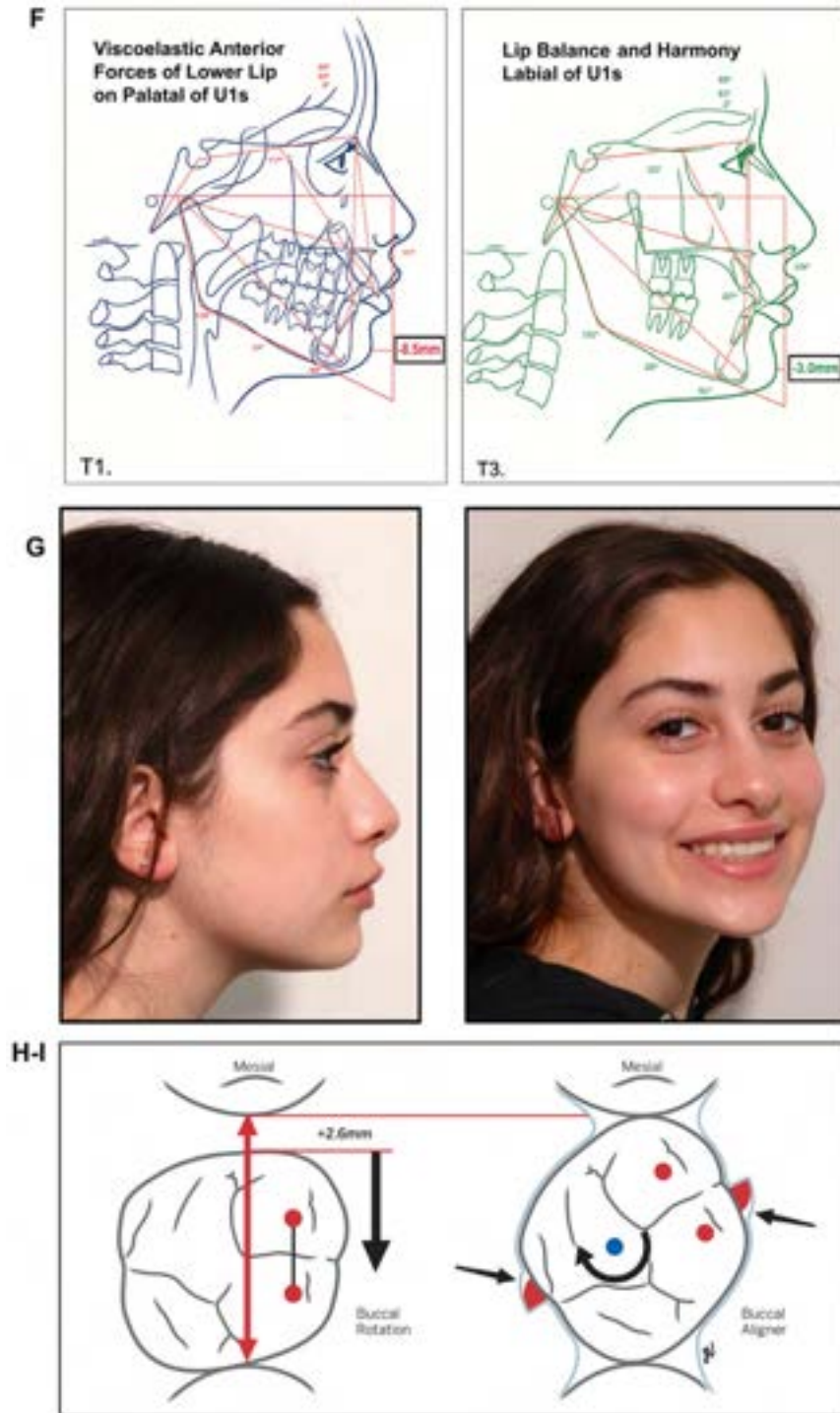


Fig. 13F-I. F. Good facial harmony and balance with good smile esthetics follow simple Stage 2 maxillary segmental distalization to specifically balance anterior lower lip forces away from the palatal of upper incisors. G. The initial transfer cephalogram and final tracings show an improved profile type with Class II correction. H. Bonded JVB at the U6s has high rotation of 35-40°. Effective U6 distalization with molar de-rotation of the buccal cusps parallel to the midpalatal suture produces an average 2.6mm of additional space for each side for a total of 5.2mm of upper arch space with the JVB. I. In contrast with aligners alone, excessively round molar shapes can lead to dental lag of three-rooted U6s and U7s³² resulting in successive aligner flexing of approximately 10° on attachments (arrows) due to slipping, aligner stress relaxation, and reduced forces within 1-3 days.^{27,28} Buccal and lingual aligner attachments are used effectively to assist de-rotation of rounded molars. Verma and George 2021, in systematic review found aligners alone required a mean treatment time of 21 ± 5 months.

Aligner supercorrection for Class II severe overbite

An overbite triad for 150% supercorrection (SC) reduces the need for refinements at the end of treatment (Fig 14). It is used in complex, severe Class II overbite (OB less than 50%) treatment because of a general familial upward and forward mandibular growth direction⁵¹ and highly associated acute gonial angle (Co-Go-Gn <126).⁶⁴ In addition, the clenching forces are from the large, hyperactive masticatory muscles. While there is no single cause-and-effect, muscle activity is associated with the buccal segments remaining *skeletally restricted* and intruded that contributes significantly to the deep curve of Spee from 3s to 7s.⁶⁵ It is also well-recognized from EMG studies that muscle activity is reduced when the vertical dimension of the lower anterior face height is increased with overbite correction.⁶⁶⁻⁶⁹ Gender is an additional important and significant consideration.⁷⁰

Muscle hyperactivity, masseter size,⁷¹ and bite forces^{70,72} (as an effect rather than cause of a short face⁷³) are particularly high at the L4s, L5s and L6s ranging for patients from 200N to 1400N (20-143kgf) using a fluid dynamics device chairside (Innobyte™, Kube Innovations, Montreal). These muscle and bite forces guide the protocol for overbite supercorrection of the curve of Spee to be between the range of 150–200% overbite correction. The initial scientific support, for the 200% supercorrection for deep overbite $\geq 50\%$ in a recent protocol here, is from a recent investigation showing the virtual treatment plan over-predicts overbite reduction in 95% of patients. However, only an average 40% of the prescribed overbite reduction is expressed.⁷⁴

This helps distort the plastic drastically like a stainless steel rectangular wire with reverse curve of Spee in aligner treatment of severe deep overbite⁷⁵⁻⁷⁷ *The virtual and clinical overbite corrections are not equivalent in complex musculoskeletal malocclusion. The virtual overbite correction needs to be supercorrected to -10% in order to achieve an average 20% clinical overbite or 2.5 mm. From the long-term data muscle and bite force are also relevant because overbite relapse is one of the highest.*⁷⁸⁻⁷⁹ *This is particularly true for adults treated commonly today with aligners.*⁸⁰ It also requires ideally an anterior bite plane with metal mesh U2-U2 just below the incisal edges for bedtime retention to counter

continuous clenching and muscle hyperactivity that will otherwise re-intrude the premolars and molars.⁸¹

It will not be surprising that a sophisticated aligner company will begin to include this mining of muscle data and bite force data in the virtual set-up to help reduce both, and consequently the inordinate numbers of refinements.

Guide #20 For deep overbite prepare aligner Progressive Posterior Eruption to reverse the curve of Spee (RCS) for the lower arch (Fig 14B, and occasionally a mild Compensating Curve (CC) aligner for upper arch). Buccal rectangular bonds are used at the upper and lower 7,6,5,4,3s to over-extrude the first molars and premolars progressively an average 200% for rapid correction of initial deep overbites $\geq 50\%$ without molar intrusion.

For overbites <50% again, supercorrection is closer to 150% because aligners covering the dentition challenge extrusion (where L4s, L5s, L6s have been *skeletally restricted* from erupting).

Guide #21 The L6s, L7s tend to tip-back with RCS. Vertical bonds are applied on the lingual to lift vertically and assist the buccal bonds. This is similar to lifting on bootstraps that reduces this molar tip-back and intrusion reaction that will need to be interscoped for finishing (Fig. 14A).

Guide #22 The extrusion forces on the premolars are labial to the center of resistance of the premolars and lower dentition shown. In severe overbite, rectangular bonds are placed on the lingual of the premolars for bodily extrusion, to maintain the curve of Wilson and anchorage (molars have vertical bonds, Fig. 14).

Guide #23 Class II elastics are placed on bondable buttons at the L6 and U3 aligner hooks for esthetics. The L6s also have shorter rectangular bonds at the mesio Buccal cusps for anchorage to resist intrusion, as the vertical dimension is opened through bodily premolar and first molar extrusion (Fig. 14A).

Guide #24 Differential extrusion is recommended in Class II malocclusions, where greater over-extrusion is programmed into the lower arch to move the buccal segments forward assisting the Class II correction, and it is greater than the over-extrusion in the upper arch that can be reduced. A narrower labial attachment is placed on the mesioangular impaction of the right L7 for uprighting and again maintenance of the vertical dimension (Fig. 14A).

A clinical concern is the proclination of the lower incisors off basal bone with Class II elastics that has a high susceptibility for relapse from the extensive literature.⁸²⁻⁸⁹ Wider rectangular bonds can be programmed on the lower incisors to

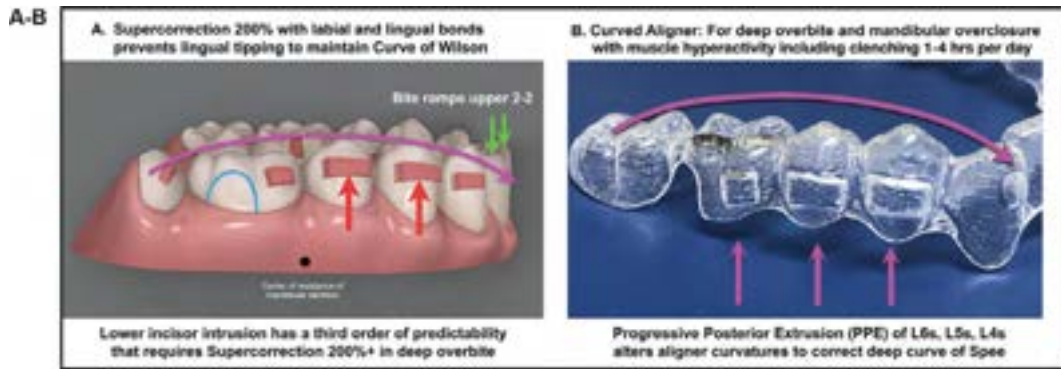


Fig. 14A-B. *A. The standard is the final virtual treatment plan must look irregular. It needs to be distorted to alter the aligners for the desired result in highly complex malocclusions. What is seen in the video as overbite correction is not expressed or achieved clinically. Three steps are shown above to supercorrect the curve of Spee and severe overbite of the software for clinical leveling. Four bite ramps assist lower incisor intrusion and bite ramps can move automatically and progressively to the incisal for greater contact. Lingual vertical or horizontal bonds are also used for control to prevent the reaction of terminal molar intrusion that needs final detailing. Note, depending on incisor display mild upper compensating curve can be occasionally applied to facilitate rapid, deep overbite correction. Aligners cover the occlusion and are pressured by clenching forces of the muscles. Deep curve of Spee has been highly associated with clenching and hyperactivity of the medial pterygoid and masseter muscle sling with hyperactivity of the temporalis muscles. B. This is the reason the aligners are altered by curving the plastic.*

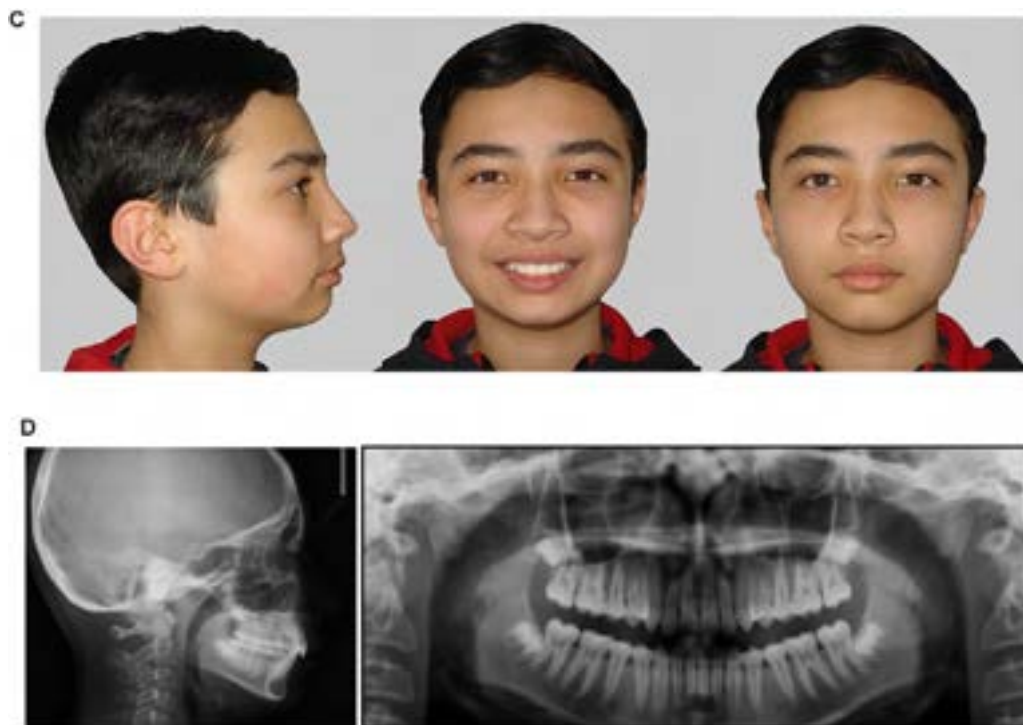


Fig. 14C-D. *C. A patient age 12 presents with a retrognathic mandible, a Class II severe, deep overbite and lower lip eversion. A high IMPA of 99° confirms lower incisor proclination that is not uncommon in deep overbites. D. The initial panorex shows the general deep curve of Spee with relative upper and lower incisor over-eruption and unerupted four third molars.*

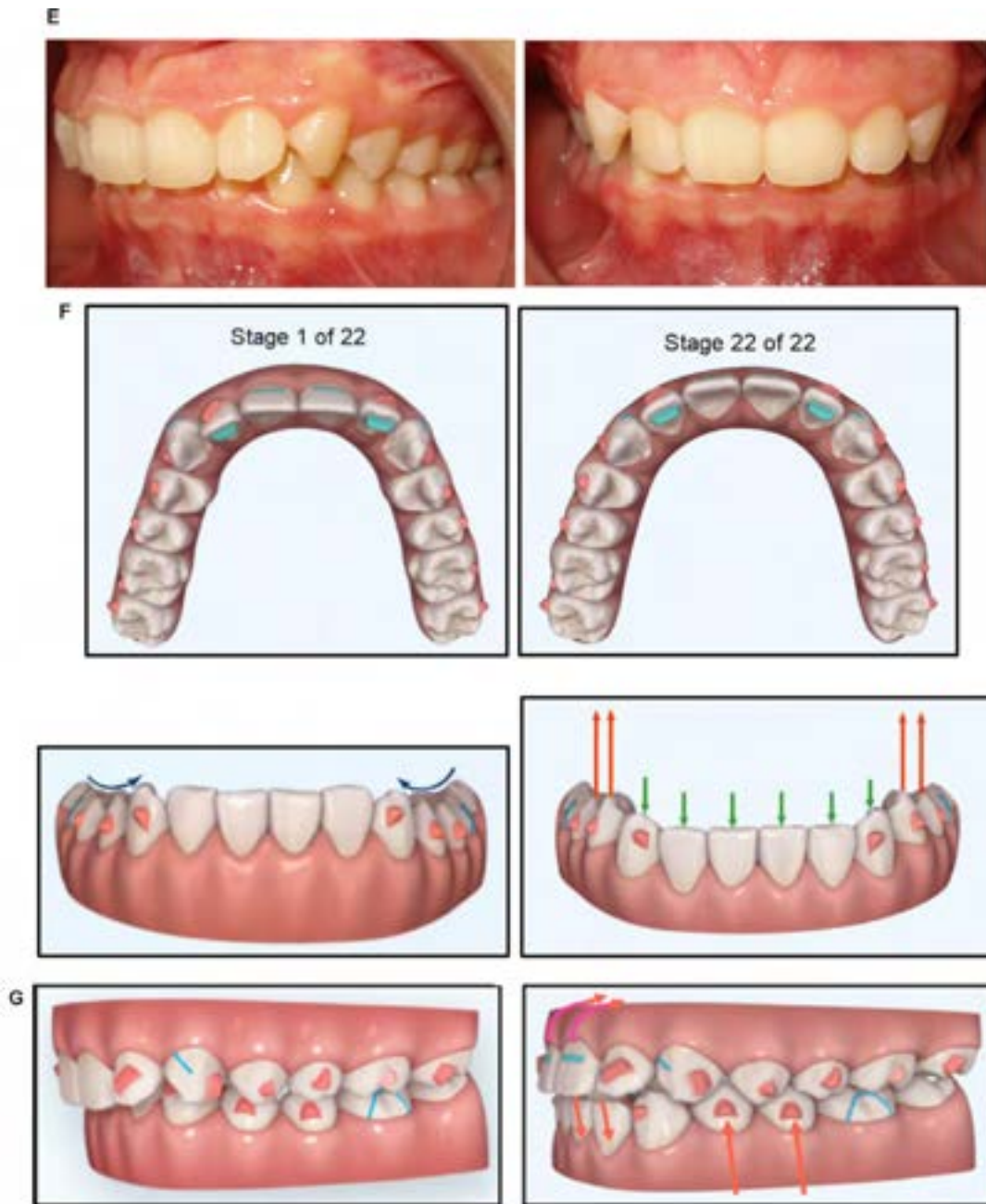


Fig. 14E-G. E. A Class II division 2 malocclusion with over-erupted incisors are present in conjunction with a deep mandibular curve of Spee. F. Bite ramps are placed at the palatal of the upper lateral incisors to facilitate physiologic and active eruption of the buccal segments. Differential supercorrection is planned for palatal root torque of the upper central incisors with power ridges™ to permit Class II elastics to mildly modify the mandible forward. The initial lower arch shows the steep curve of Spee (blue curves). Differential supercorrection includes progressive extrusion of the premolars (and lower first molars), with simultaneous intrusion of the lower canine-to-canine region for effective step-down aligner biomechanics. G. On the right, the upper incisors demonstrate the 200% supercorrection of torque required to permit the mandible to mildly modify forward shown with Class II elastics. In addition, the deep overbite is ideally 200% supercorrected in anticipation of relapse, that is common with overbite correction. The rationale for planning differential supercorrections is that they are not fully expressed by flexible aligners. For this reason, it is necessary to have an overcorrected set-up shown in Figs. F and G to achieve the goals of maxillary incisor torque and to fully correct the deep overbite clinically. This makes finishing results more predictable. A total of 22 aligners changed approximately every 2 weeks are used over the first 10 months of treatment. Note, bite ramps and attachments cannot be applied with power ridges™ on the same dental units shown in F above.

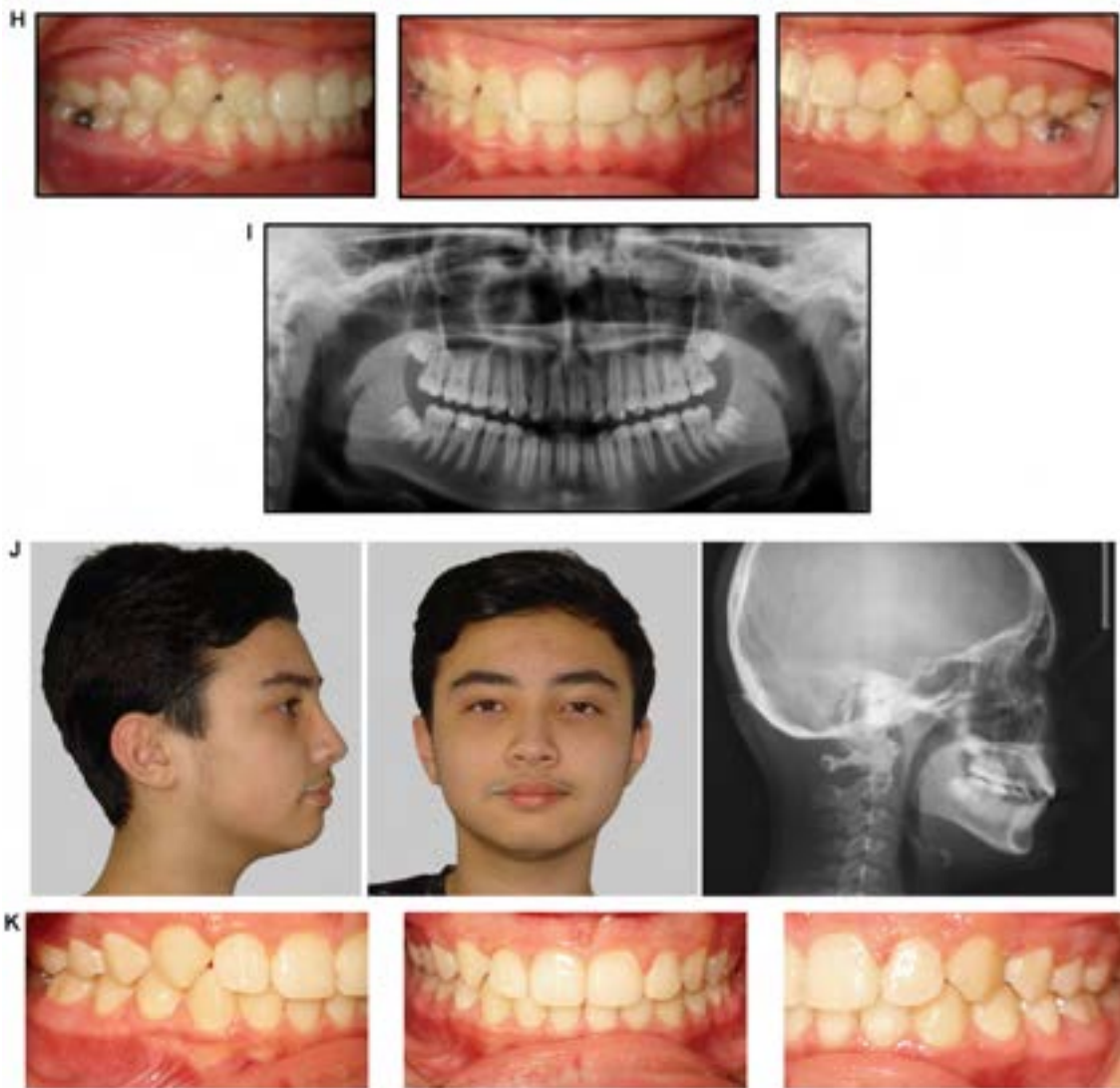


Fig. 14H-K. **H.** At the 10-month evaluation, with 4 visits to the office for the completion of the first 22 aligners, the upper lateral incisors required further refinement and a scan was taken. Aligner bondable buttons with a triangular base (DynaFlex® Precision™) on the lower molars are used for Class II elastics. Initial correction of the deep overbite is shown with lower premolar and first molar extrusion and reciprocal active anterior upper and lower intrusion. **I.** The progress panorex following 10 months of aligner wear demonstrates the reversal of the curve of Spee. There is also an indication of good overall root integrity with the appearance of significant intrusion of the lower canine-to-canine region in conjunction with mild upper incisor intrusion. **J.** Good face-lip balance is associated with a harmonious facial type following the aligner therapy. The lateral cephalogram confirms the corrected upper incisor torque and the flattening of the curve of Spee following the 200% supercorrections on the software. **K.** A good Class I intercuspation is achieved with significant correction of the overbite after a total of 16 months of aligner treatment (with the refinement) for a total of only 7 actual visits to the office. Differential supercorrection of lower premolar and first molar extrusion is effective in conjunction with anterior intrusion. Supercorrection of 200% for the upper incisor torque serves to upright the central incisors and align the U2s.

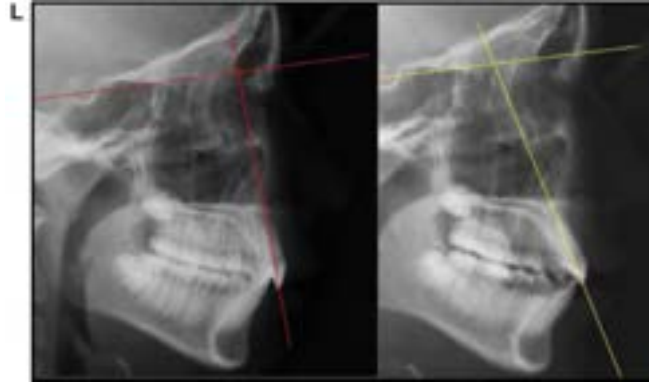


Fig. 14L. A comparison of the initial upright position of the central incisors shows a SN to U1 angle = 92.5° (left). Following digital treatment planning with aligners using supercorrection of palatal root torque for the U1 the SN to U1 = 104.5° . This difference demonstrates total palatal root torque of $+12.0^\circ$ with supercorrection incorporated from the beginning into the virtual treatment planning of thermoplastic aligners.

advance the lip, resulting in backward directed force on the incisors preventing relapse.

Guide #25 The amount of incisor intrusion depending on upper incisor display needs to be 200%+ higher supercorrection on the virtual treatment plan (Fig. 14). The reason is the aligners are not able to intrude the upper and lower incisors easily in severe overbites. Again, the amount of upper incisor intrusion with a gummy smile will not be fully expressed and will also depend on how much more the lower incisors can be intruded differentially. In severe overbites with vertical maxillary excess and gummy smiles due to incisor over-eruption, consideration should ideally be given to apply additional rectangular bonds at the upper and lower incisors to intrude them and supercorrect the deep overbite to -10% in the virtual set-up (shown in Fig. 14G). This is ideal preparation for good overbite retention.

Guide #26 Apply curved bite ramps near the incisal edges in deep overbite on the U1s and U2s to disocclude the premolars for extrusion, and facilitate incisor intrusion. Place bite ramps on the U3s initially when severe overbite and severe overjet are present together and the protruding incisors cannot be reached A-P by the lower incisors (Fig. 10). Blue ionomer resin at the molars is contraindicated in deep bites because they intrude the molars chronically that exacerbates the deep overbite and lengthens treatment time unnecessarily.

Aligner technique for open bite treatment: 3-main steps

Guide #27 Aligner supercorrection planned for severe open bite has 3-steps to reduce requests for extensive refinements or re-treatment due to a high incidence of relapse. Open bite may often be associated with chronic nasopharyngeal obstruction,⁹⁰⁻⁹⁶ 2° chronic mouthbreathing with molar over-eruption and 2° anterior tongue positioning⁹⁷⁻¹⁰⁰ (Fig. 15). Bite force and EMG muscle activity is lower in adults with long anterior lower face height than with skeletal deep bite.⁷³

It is not a secret that open bites are also one of the most complex to treat and most difficult to retain long-term.¹⁰¹ The total thin flexible aligner material of 1.5 mm ($2 \times .75$ mm) has been found to be good clinically for initial chewing¹⁰² but it is *not always sufficient to intrude the buccal segments effectively and efficiently to supercorrect the overbite toward the +30% goal needed.* The reasons are often hypoactive chewing muscles associated with the chronic nasopharyngeal obstruction, 2° mouthbreathing and anterior tongue positioning (Fig. 15).

Guide #28 Incisor extrusion in open bite treatment is unstable and needs to be combined with greater progressive buccal segment intrusion to avoid anterior relapse. For crowded, intruded incisors covered by the lips and poor esthetics, there are 2 Stages for

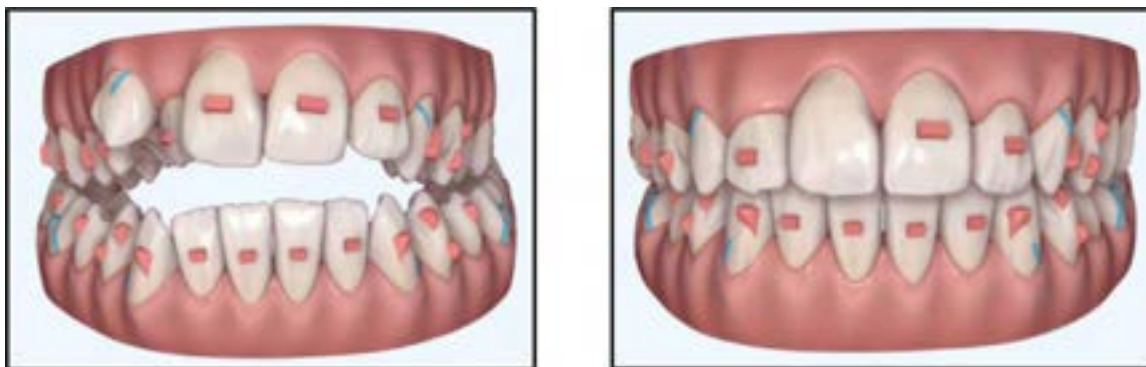


Fig. 15. Pre-treatment severe open bite (left) and post-aligners, on right with “not enough overbite of 30%”

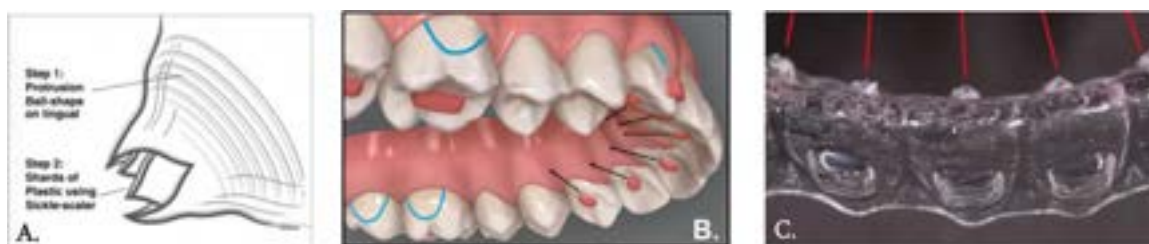

Fig. 16A-C. **A.** Aligner Tongue Trainers (ATTs) use **B,** 6 elliptical bonds shown on palatal of upper incisors *unfilled*, and prior to puncture. **C** shows 5 of 6 lower ATTs are punctured with a scaler from lingual, and labial bonds upper, and lower (shown at bottom) 3-3 are used for relative extrusion as molars are intruded reciprocally when indicated in a reverse smile.

upper and lower incisor extrusion a) create space first b) extrude while simultaneously retracting mildly the same amount where extrusion occurs naturally here at the middle of open bite treatment.

The 3-Main Steps for Aligner Open Bite Treatment

Guide #29 ENT Consultation, Allergist Evaluation, and Nasal Rinse first.

The protocol uses first ENT and Allergy consultation, with natural, 0.5% to 1.0% sea salt nasal spray q 12 hrs as a natural nasal cleanser and anti-inflammatory (Salinex™) used for infant rhinitis. This includes chronically inflamed turbinates visible on a frontal cephalogram (Fig. 19D), tonsils and adenoids. Note, septal deviation and sinusitis can also contribute to nasal obstruction with habitual, 2° mouthbreathing in skeletal open bite.

Guide #30 Aligner Bite Blocks, Progressive Posterior Intrusion (PPI)

Since anterior tongue position has been associated with the maintenance of the open bite the second Open Bite Triad applies **i)** 12 Aligner Tongue Trainers (ATTs) where unfilled elliptical

bonds are punctured for small 1.5mm diameter, lingual, plastic shards upper and lower 3 to 3. This reminds the strong tongue muscles to retract from the anterior opening (Fig. 16) but the shards do not cut the tongue. Bite ramps *have not* been effective as tongue trainers and contraindicated in open bite.

Guide #31 A maximum + 30% overbite should be programmed into the aligners in preparation for return of the original open bite, and some delay of full aligner expression observed.

ii) The next component applies Aligner Bite Blocks (ABB) upper and lower that can be made with bonds 1.5 mm high, flat and wide across the entire occlusal surfaces of 7's. Alternatively, the horizontal bite block bonds can be approximately 4 mm long × 1.5mm high through the central grooves, and placed on the computerized set-up ranging from the upper and lower 7s, 6s and can include 5s, and 4s (Fig. 17).

Guide #32 Aligner Bite Blocks (ABBs) are an adjunct in mild open bite 0 to +10% minimal overbite. The ABBs are unfilled in the plastic to intrude the buccal segments

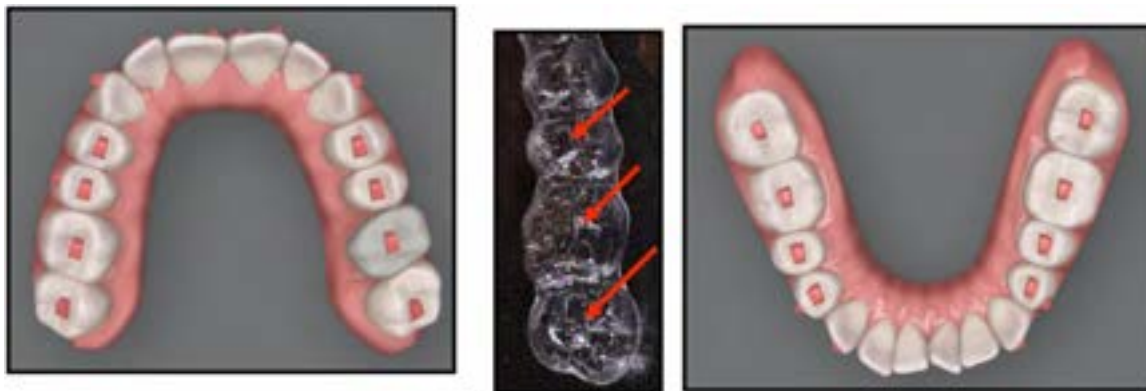

Fig. 17. Aligner Bite Blocks (ABB) are applied independently in milder open bites 0 to +10% for posterior intrusion, and are *unfilled* for maximum molar intrusion.

with a flexible bounce effect. (This is similar to how voids are used under bite ramps). In this way, when the patient is eating without aligners there are no occlusal resin interferences for chewing (Fig. 17). Patients are instructed to consistently and gently chew down on the Aligner Bite Blocks for posterior intrusion.^{103,104,105}

Guide #33 In severe open bite > 0% upper and lower, progressive posterior intrusion (PPI) starts for 4s at 1.5 mm and increases at increments of .5mm extending to 5s at 2 mm, 6s at 2.5 mm, and 7s at 3 mm (Fig. 18), if 4s and 5s are over-erupted and in occlusion, as part **iii**) of the Open Bite Triad. Local buccal horizontal bonds can also be applied, and all third molars are extracted to prevent over-eruption of e.g. 1mm at posterior, opening the vertical approximately 3 mm anteriorly like an occlusal wedge (Fig. 18). In the finishing stage, mildly refine any intruded molar cusp tips and marginal ridges at the last set of aligners for ideal intercuspation to lock the occlusion in retention. This prevents the strong tongue, that fills spaces in the posterior, from re-opening posterior interocclusal spaces.

Guide #34 Autorotation of the mandible in a counterclockwise direction¹⁸ occurs with progressive intrusion of the buccal segments assisting correction of the Class II malocclusion toward a Class I occlusion (Fig. 18A-N), and with TADs (Fig. 19A-L). Clinically the facial type is observed to be more orthognathic and the profile type straighter by

rotating the mandible upward and forward with upper and lower progressive, buccal segment intrusion. It is important that sufficient lower incisor IPR with retraction needs to be virtually planned to prevent anterior interferences during counterclockwise mandibular autorotation.

Since extrusion of the small incisors is difficult, unstable and can exacerbate a gummy smile, it should be largely avoided, with the focus on progressive buccal segment intrusion above. The exception is a reverse smile, or often, if initial incisor intrusion is visible from a frontal smile with lack of incisor display. This upper and lower incisor intrusion is commonly associated with chronic anterior tongue positioning that fills the anterior bite space. For these patients, space is made first for the crowding. This is followed by simultaneous mechanics, with mild extrusion of the upper and lower incisors using beveled gingival bonds with a light anterior box-pattern elastic force of 3/8", 2.5oz (Figs.18B) that reduces the risk of incisor root resorption.

Guide #35 For long-term retention, following aligner therapy, prescribe with PPI Chewies for posterior intrusion with:

1) Sugar-free, aspartame-free gum (Pure™, or natural Chios Mastic gum) is recommended for the majority of open bite patients. This strengthens the chewing muscles 15 min at a time, 3 times daily when active aligners are off for 1hr/day, and throughout retention, as long as there are no symptoms of TMD.

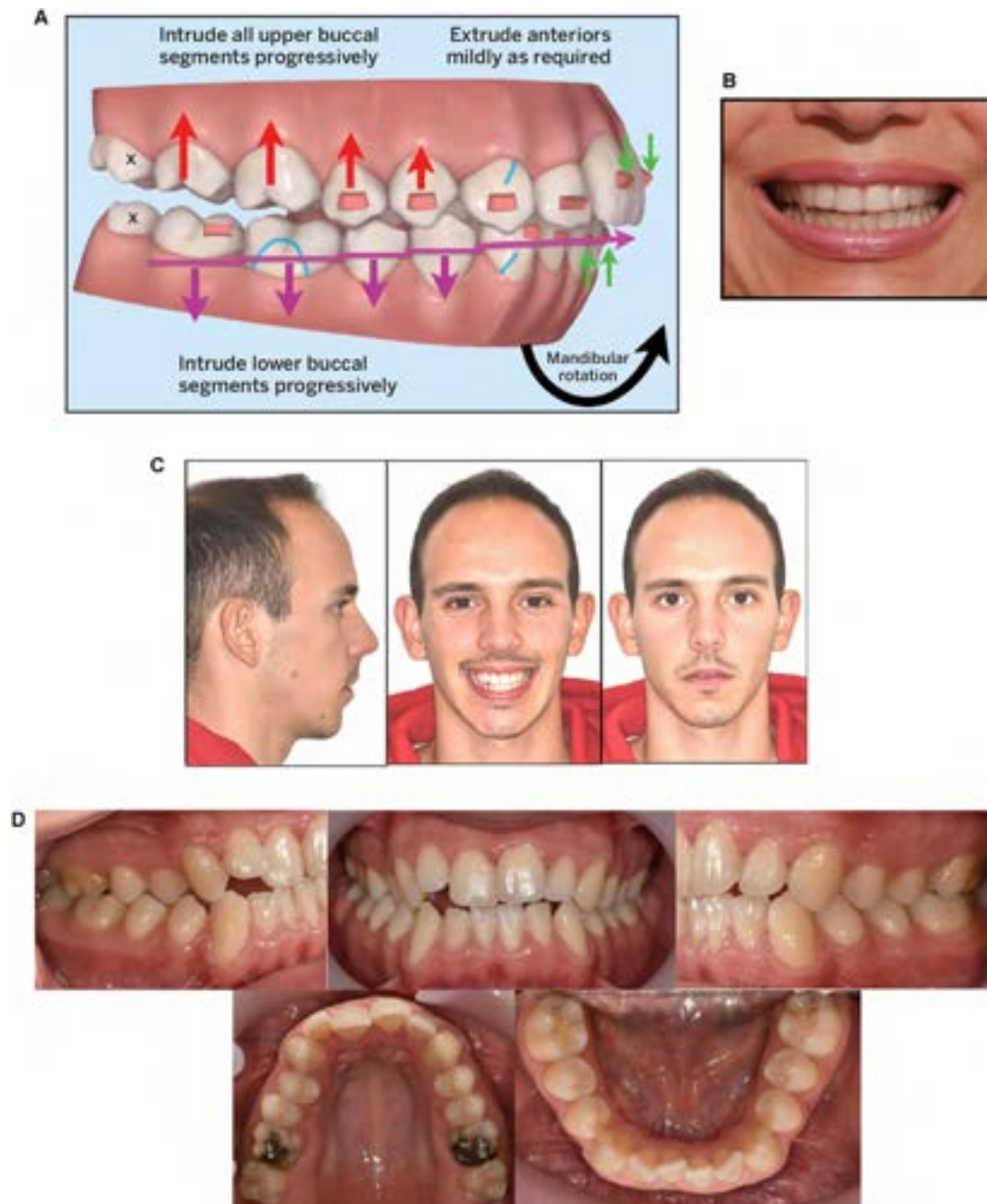


Fig. 18A-D. A. Progressive posterior intrusion of the upper and lower buccal segments closes the anterior open bite and rotates the mandible forward. The third molars are extracted for purpose of open bite closure (curve of Spee alone for the lower arch is not recommended because it leaves L7's higher occlusally). B. Anterior Box-pattern Elastic (ABP) 3/8", 2.5 oz on the upper right may be considered if incisors are intruded when smile is not gummy. C. Patient age 16 presented with mandibular retrognathia, anterior open bite in the incisor area and moderately constricted dental arches with difficulty biting anteriorly. D. Crossbite was present at the UR4 associated with functional shift of the mandible to the right of the facial midline. A long anterior lower face height was present with a steep MP-SN = 39.7° Extraction was not ruled out to prevent incisor proclination (IMPA 92.6°) that could exacerbate the open bite and affect long-term retention, without fixed retainers.

2) A lower bite block is additionally prescribed with a 2.0 mm thickness at the posterior L6s with a lingual bar connector. The bite block regions extend from the 7s to cover the 4s bilaterally. The bite block is worn at night to continue to maintain the buccal intrusion.

Guide #36 TADs can also be placed in severe open bites¹⁰⁶ on each side of the buccal and palatal of the U6s. Following upper aligner insertion, the patient “wraps” a heavy 3/16” 6.5 oz elastic locally across the occlusal surface of each upper molar to supplement intrusion. Elastics are changed daily.

Dental anomalies: congenitally missing upper laterals with space loss

The roots of the U1s and U3s are often tipped into the implant space for the replacement of upper lateral incisors (Fig. 20A-D).

Correcting root tipping in congenitally missing U2s with space loss

Guide #37 Place both vertical bonds on the palatal of U1s and U3s and horizontal bonds (or alternatively beveled gingival bonds) on the labial for 200% supercorrection in a “T-Design” (Fig. 20D). Two opposing sets of forces per tooth on the palatal bonds and another two opposing forces on the smaller labial bonds for esthetics, result in two sets of effective moments of a couple along two planes. The labial bonds are maximum width for distal angulation of the U3 roots and mesial angulation of the U1 roots. Note, the T-Design of palatal and labial bonds are reversed for L2 angulations with vertical bonds on the *straighter* labial surface, and horizontal on the lingual surfaces. The second reason is the lower lip covers the labial

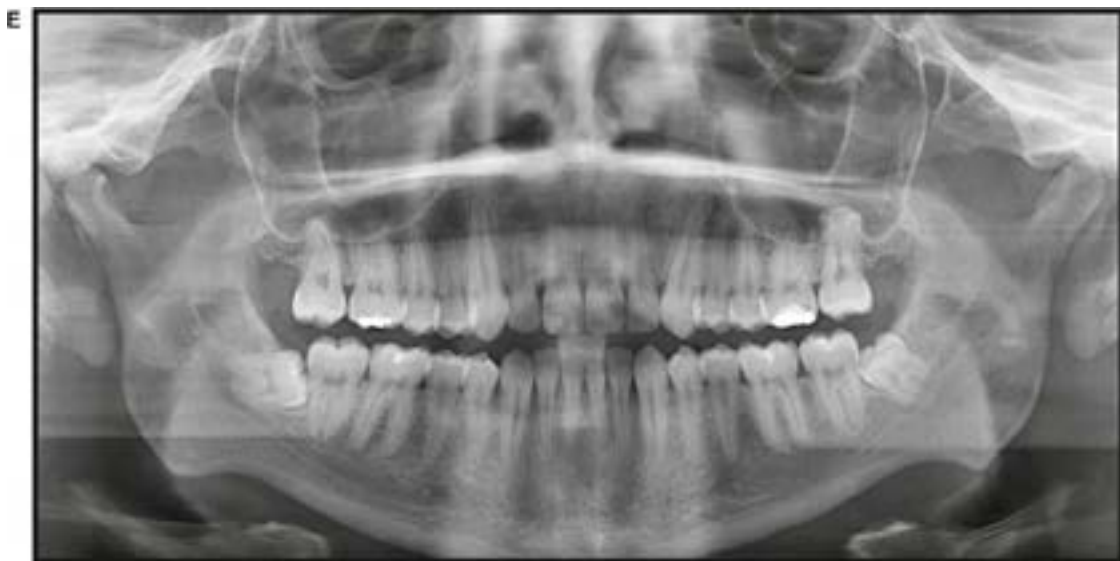

Fig. 18E. The panorex radiograph revealed potential nasal obstruction related to enlarged turbinates and panorex is ideally emailed with CBCT to the physician, ENT and Allergy Specialists with parents. The root morphology and other skeletal structures were within normal limits and the mandibular third molars had mesioangular impactions. Prophylactic extraction was recommended to the patient.

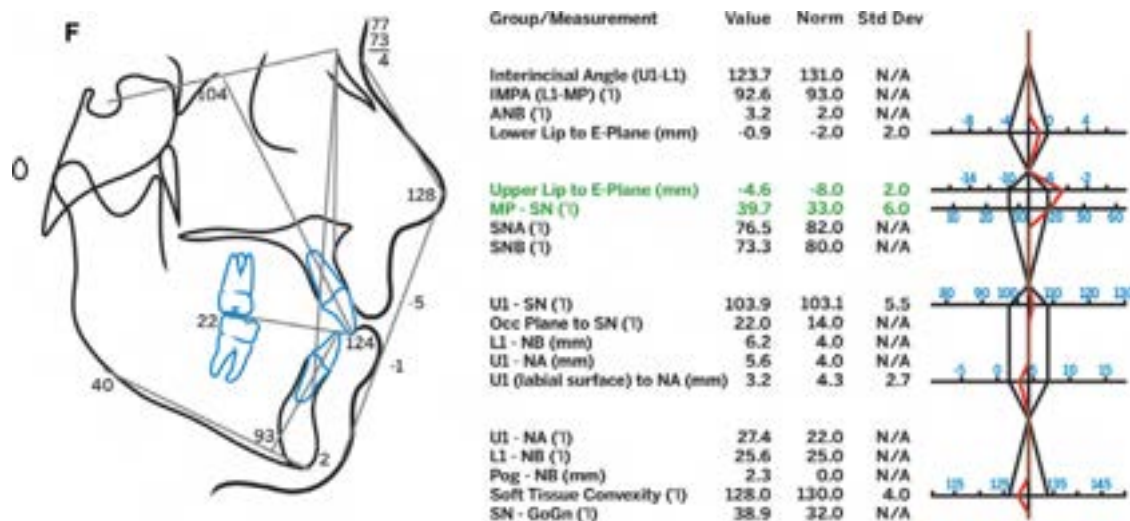
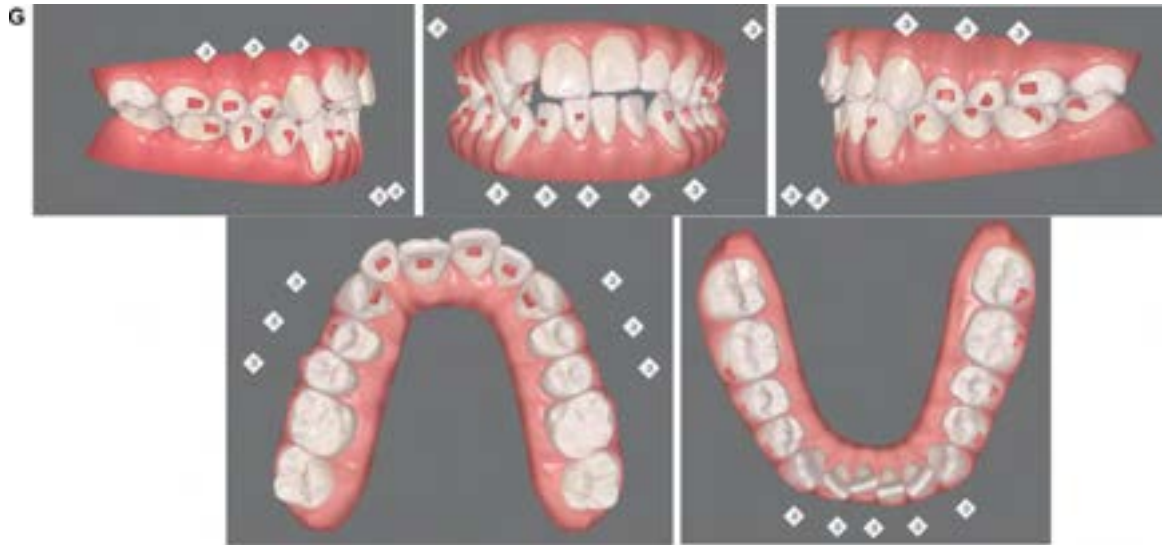

Fig. 18F-N. **F.** The cephalometric analysis revealed a Class II skeletal retrognathic pattern with normal inclination of maxillary and mandibular incisors, and a moderately increased Frankfort mandibular plane angle FMA = 29° (average 26°). **G.** Palatal attachments were placed on the upper anteriors as the option to puncture them with a scaler from the lingual for aligner tongue trainers. The digitized treatment plan included initially twenty-four maxillary and mandibular aligners, changed q12days, worn 18-22 hrs/day. **H.** The staging included posterior expansion in the range of .5-2mm without proclination of the maxillary and mandibular incisors (see Tables). There was minimal active intrusion of 0.1mm or less of the posterior teeth. **I.** The moderate to severe crowding was well aligned in both arches with the application of moderate interproximal reduction. The expansion of the maxillary constriction was indicated because of the environmental nature of the crowding associated with the potential nasal obstruction. The patient was compliant wearing the aligners initially during the daytime between 18 and 22hrs/day. **J.** Lip seal was improved **K.** A well interdigitated Angle Class I occlusion was achieved at both the molars and the canines with an overbite of 2mm at the central incisors and midline coordination with the UR4 crossbite correction. The aligner treatment included two groups of refinements, twenty two aligners changed q 7 days worn 18-22 hrs/day followed by ten aligners changed q7days worn 12hrs/day. A clinically evident reduction of the open bite was observed, including stages when aligners were performing mild anterior extrusion, (that had not been used). In the first refinement aligner group the maxillary anteriors were extruded mildly 0.9mm and the lower anteriors extruded 0.4mm. The velocity of movement was additionally reduced by 50% to take advantage of the passive posterior intrusion in the first refinement. **L.** The final panorex revealed good root parallelism and normal skeletal morphology with no apparent evidence of root resorption. Removable Vivera™ clear retainers with full occlusal coverage were used for nighttime wear. The impacted mandibular third molars remained under observation with general dentist. **M.** Cephalometric analysis revealed a reduction in the anterior lower face height due to mandibular autorotation. The maxillary and mandibular incisor IMPA = 91.7° angulation was maintained. **N.** The superimpositions showed a reduction of the lower anterior face height associated with intrusion of the mesial cusp tips of the maxillary and mandibular molars resulting in counterclockwise mandibular autorotation. All treatment objectives were achieved, and treatment time was maintained with 56 aligners (24+22+10). The total treatment time was 17 months with an overall average change of aligners once every 8.5 days.



H

Teeth movements table

	186	187	188	189	194	195	192	191	111	112	113	114	115	116	117	118
Extrusion/Intrusion, mm	0.11	0	0.22	0.08	0.08	2.48	1.62	2.02	0.18	0.18	0.48	0	0.18	0	0.18	0
Relative Ect/Ret, mm		0.11	0.21	0.11	0.01	0.48	2.38	1.18	2.38	0.18	0.78	0.11	0.21	0.18	0.18	0.21
Translation, BL, mm	0.01	0.01	0.01	0.01	0.01	0.01	0.01	0.01	0.01	0.01	0.01	0.01	0.01	0.01	0.01	0.01
Translation, MD, mm	0.01	0.01	0.01	0.01	0.01	0.01	0.01	0.01	0.01	0.01	0.01	0.01	0.01	0.01	0.01	0.01
Rotation, °	0.20	4.00	0.40	0.70	0.70	7.00	0.20	0.20	0.20	0.20	0.20	0.20	0.20	0.20	0.20	0.20
Angulation, °	0.10	0.10	0.10	0.10	0.10	0	0.10	0.10	0.10	0.10	0.10	0.10	0.10	0.10	0.10	0.10
Inclination, °	1.18	0.41	0.18	0.78	0.48	7.21	0.28	0.41	1.48	0.08	0.38	0.08	0.18	0.18	0.18	0.18

Upper Lower Teeth basis Crown Foot

Teeth movements table

	186	187	188	189	194	195	192	191	111	112	113	114	115	116	117	118
Extrusion/Intrusion, mm	0.21	0	0.18	0.78	0.08	1.38	0.08	0.18	0.11	0.41	0.18	0	0.11	0.11	0.11	0.11
Relative Ect/Ret, mm	0.21	0.01	0.48	0.78	0.08	1.18	0.08	0.11	0.11	0.41	0.11	0.11	0.11	0.11	0.11	0
Translation, BL, mm	0.01	0.01	0.01	0.01	0.01	0.01	0.01	0.01	0.01	0.01	0.01	0.01	0.01	0.01	0.01	0.01
Translation, MD, mm	0.01	0.01	0.01	0.01	0	0.01	0.01	0.01	0.01	0.01	0.01	0.01	0.01	0.01	0.01	0.01
Rotation, °	0.40	0.01	7.30	2.70	0.00	20.20	0.40	0.30	20.30	20.30	0.40	0.00	0.20	0.20	0.20	0.20
Angulation, °	1.00	0.10	0.20	0.40	0.00	1.10	0.30	0.70	0.00	0.00	0.10	0.10	0.10	0.10	0.10	0.10
Inclination, °	0.38	0.08	0.01	1.21	0	0.21	0.08	0.08	0.48	0.08	0.48	0.08	0.08	0.08	0.08	0.08

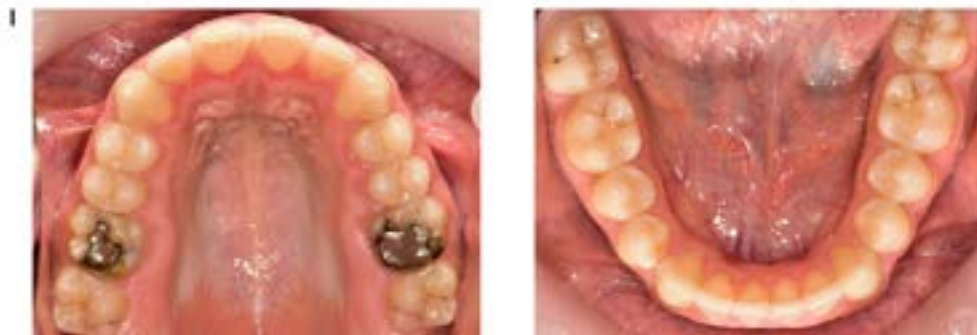

Fig. 18F-N. Continued

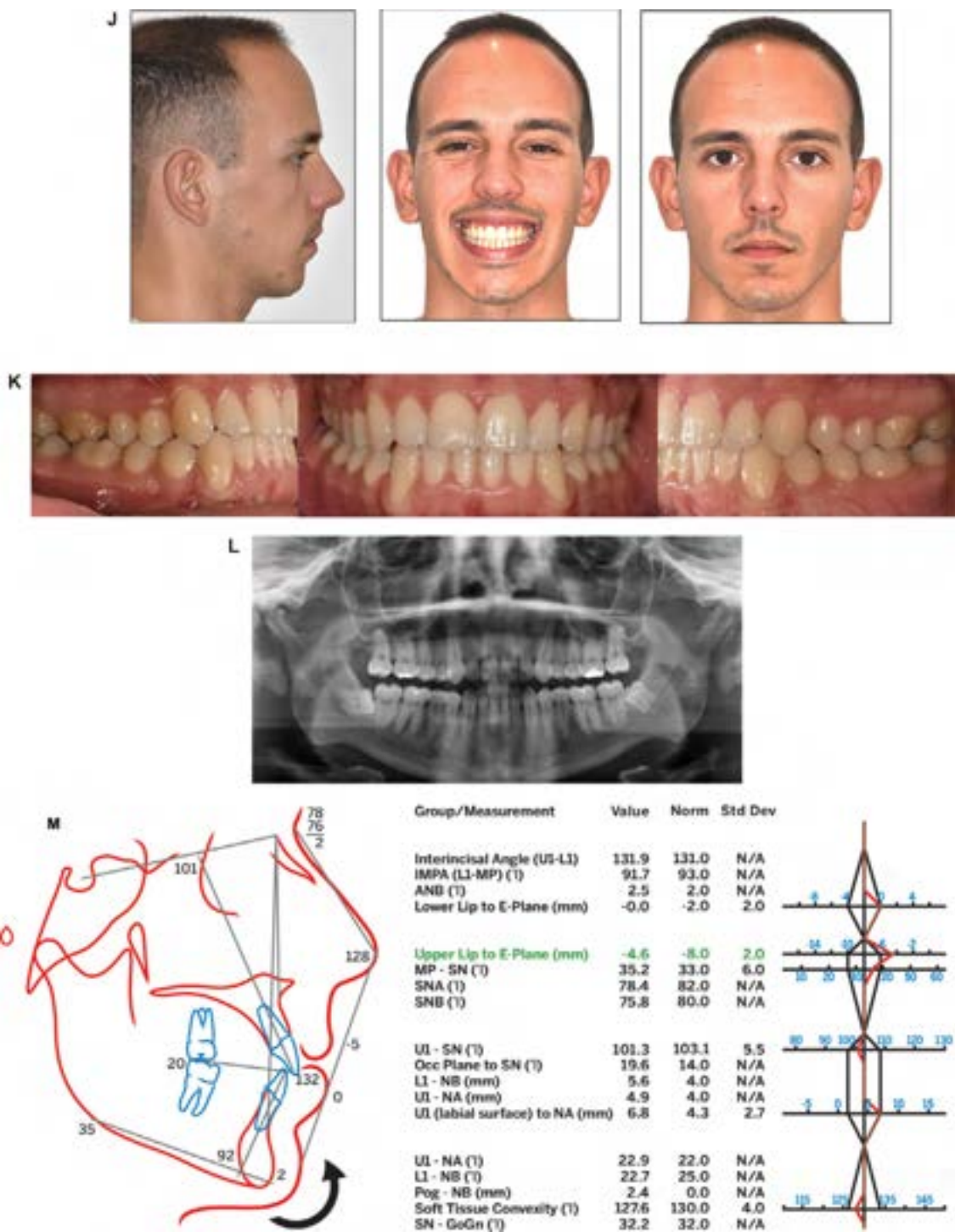


Fig. 18F-N. Continued

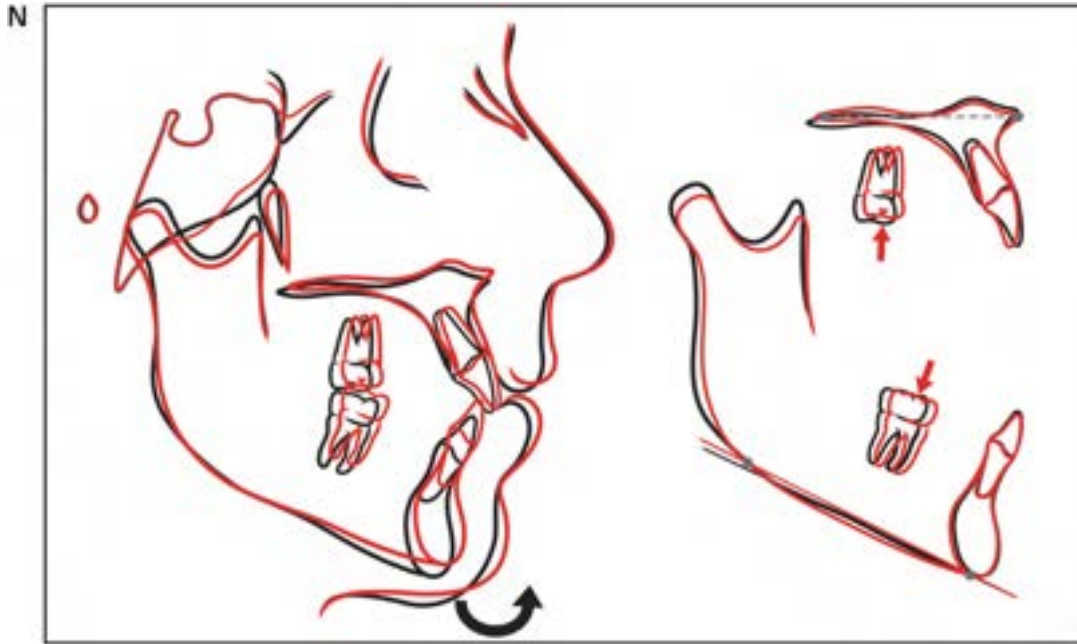


Fig. 18F-N. Continued

vertical bonds more whereas, the upper incisors are more visible (Fig. 6B, C, D).

Guide #38 Request initially thin pontics (P) at missing U2 areas to push directly on interproximal dental surfaces, for effective Stage 1 space-regaining.

2. Generalized Upper and Lower Spacing: It is important to identify from the panorex initially which of the tipped roots are likely to tip further and rotate during space closure.

Guide #39 In deep overbite with generalized spacing first intrude incisors to prevent incisor extrusion and

place L6,5,4,3 rectangular bonds to hold the buccal segments vertically that prevents deepening the curve of Spee. In Stage 2 of incisor retraction, the buccal rectangular bonds continue to prevent a reciprocal compression of the curve of Spee anteroposteriorly and deepening of the overbite.

Guide #40 When there is a concern that the contacts are not tight enough for retention near the completion of treatment, program a minor amount of IPR for the incisors, but do not complete the IPR intraorally. In this way the aligners are built to

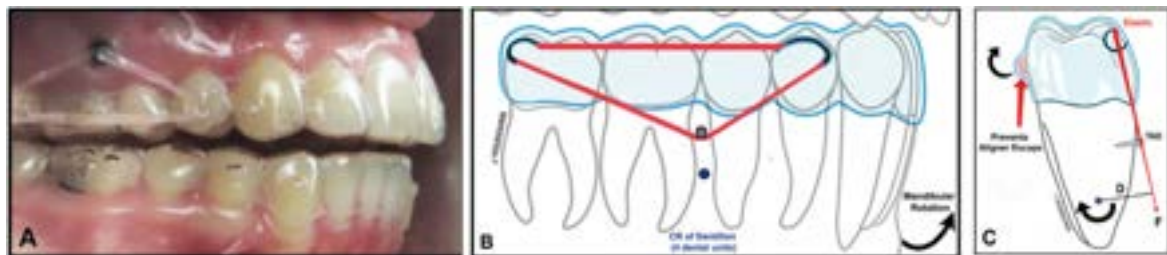


Fig. 19A-C. A. The crescent cut-outs and triangle elastic or C-T Intrusion Technique is TAD-assisted to correct the skeletal over-eruption of the buccal segments in anterior open bite by applying dentofacial orthopedic posterior intrusion with aligners and vertical elastics. B. Crescent-shaped cut-outs are made in the aligner distobuccal cusp areas at the L7 and mesiobuccal of L4 for an inverted triangle-elastic pattern (1/4", 4.5oz). This facilitates progressive posterior intrusion, and counterclockwise mandibular autorotation shown in B. The force of intrusion is near the assumed CR of the 4 dental units (blue) between the lower second premolar and first molar. C. For bodily buccal segment intrusion lingual horizontal beveled attachments are used for anchorage to prevent aligner lift or escape.

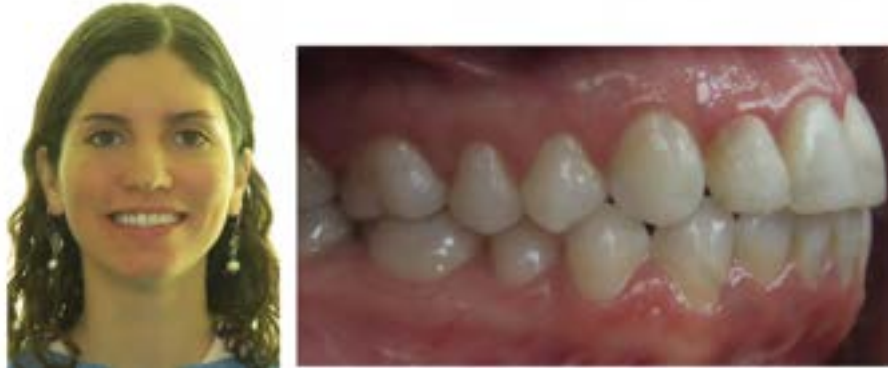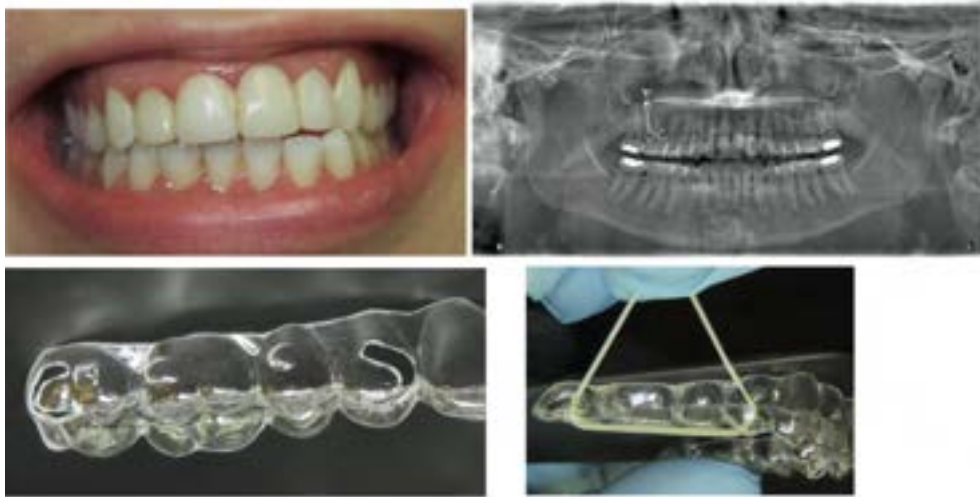


Fig. 19D. An asymmetric open bite with maxillary over-eruption in the first quadrant resulting in a cant of the occlusal plane (top left) is challenging with aligners particularly in adults. Aligners anchored to attachments apply “serpentine intrusion curvatures” for higher intrusive force in the first quadrant, while holding the second quadrant vertically. A TAD, or mini-plate anchorage unit may also be employed shown in the panorex. There is an initial appearance of nasal obstruction with enlarged turbinates and nasal airway stenosis associated with chronic mouthbreathing that requires first ENT and Allergist consultation to control the etiology of this often genetic, systemic-related problem. The two crescent-shaped cut-outs are shown at the molar and first premolar cusp areas with the elastic stretched and pre-loaded in place across the buccal of the aligner. Infrazygomatic mini-plate anchorage is selected due to the reduced interradiacular space between UR6-UR5, where TADs are preferred ideally in the C-T Intrusion Technique. The occlusal and incisal planes are leveled for good facial and smile esthetics (see summary Fig 19E).

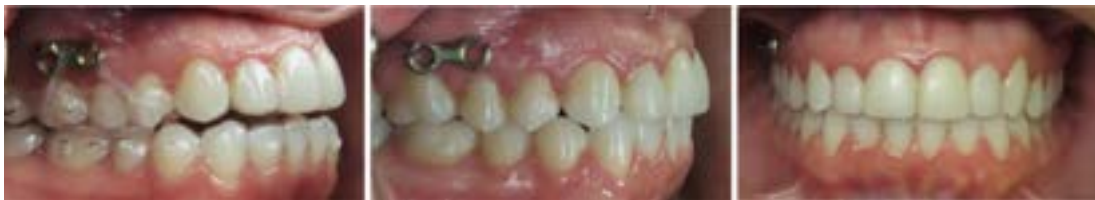

Fig. 19E. Summary of aligner asymmetry treatment. The unilateral infrazygomatic titanium plate anchorage with dual-loop hooks engage a heavy elastic for intrusion of the right unilateral, asymmetric open bite. The open bite on the right side is closed with 24 aligners changed approximately every 7 days, in 8.5 months with refinements in dentofacial orthopedics, and en masse buccal segment intrusion unilaterally on the right side. In addition, note the retraction vector of the elastic to correct the overjet, and level the cant of the occlusal plane.

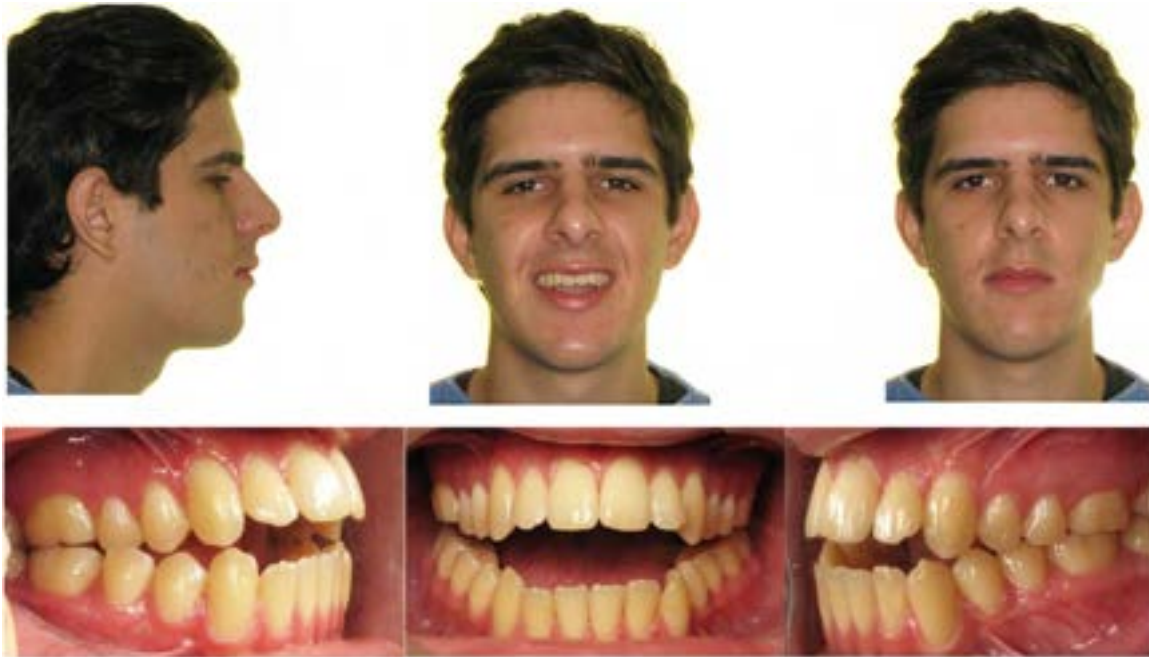

Fig. 19F. A 20 year old male with skeletal Class II division 1 Subdivision right severe open bite of -50% or -6mm is shown with moderate overjet of 4 mm and partial display of the upper incisors upon smiling. The open bite is characterized by over-eruption of the posterior buccal segments, skeletal maxillary constriction associated with chronic nasopharyngeal obstruction and secondary anterior tongue positioning. Bilateral crossbites are present with a functional shift of the mandible to the right of the facial midline. Upper and lower incisor extrusion is contraindicated to maintain smile esthetics and to reduce the risk of root resorption with extrusion. Dentofacial orthopedic upper and lower supercorrection of 200% posterior buccal segment intrusion for the skeletal over-eruption of the posterior segment is the indicated treatment plan. The goal is to *reduce and control the posterior vertical* dimension to produce horizontal Class II correction by using dentofacial orthopedic, counterclockwise mandibular autorotation.

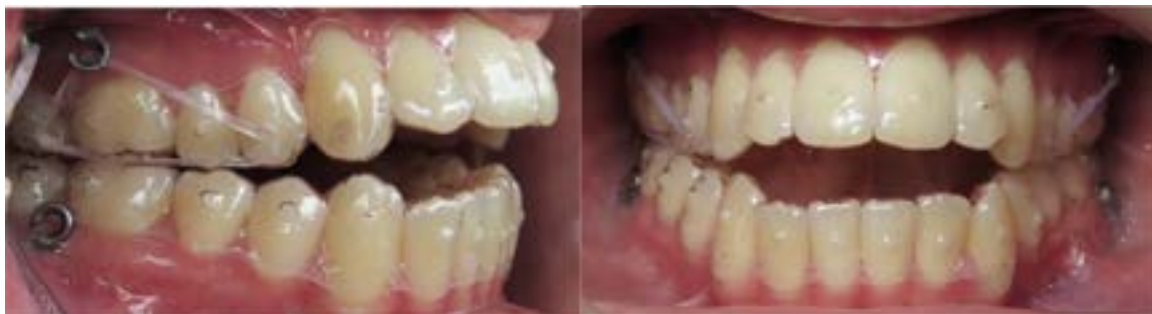

Fig. 19G. Due to reduced interradicular space between U6 and U5 regions bilateral, infrazygomatic titanium mini-plate anchorage with single loop hooks are used for an upper triangular-pattern, 5/16", 4.5 oz elastic shown for upper buccal segment intrusion. The center of resistance of the maxilla is near the zygoma and above the single loop of plate, for bodily intrusion with simultaneous retraction of the overjet.

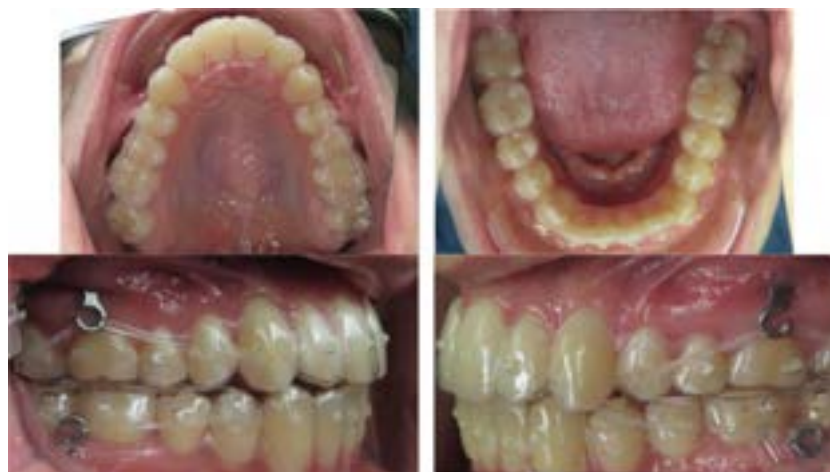

Fig. 19H. The C-T Intrusion Technique uses an elastic loaded into the upper crescent-shaped cut-outs and stretched up to the anchorage loop. Similarly, the lower elastic is engaged for bodily intrusion. This is highly effective because it is a combined double intrusion effect of the buccal segments (see Fig. 19 A,B).

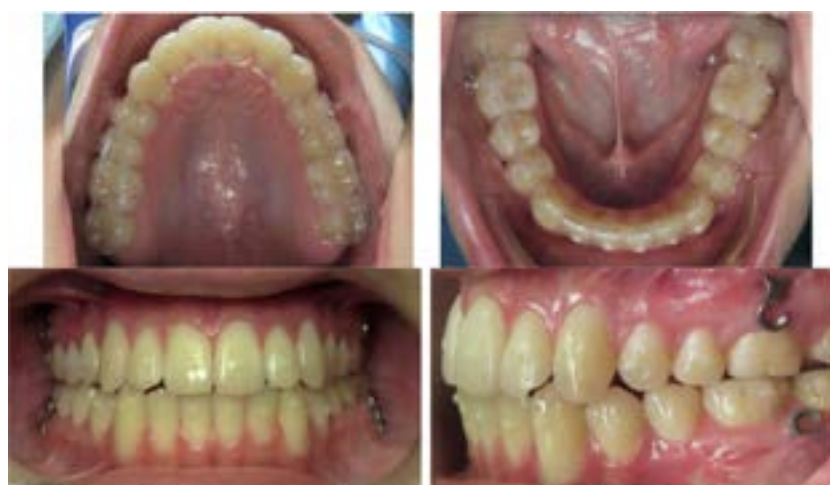

Fig. 19I. Progress records following 38 aligners changed each week for a total of 9.5 months demonstrates the expansion of the environmentally constricted maxillary arch to initiate crossbite correction. The occlusion is settled with the C-T Intrusion Technique and the thickness of the two aligners having a total bite block-like height of 1.5 mm in the posterior. The lower intercanine distance is maintained during alignment with programmed IPR. The initial dentofacial orthopedic effect is demonstrated by the closure of the open bite by 6 mm anteriorly. This is a result of bilateral upper and lower skeletal buccal segment intrusion and counterclockwise mandibular autorotation (see Progress cephalometric changes Fig. 19 K).

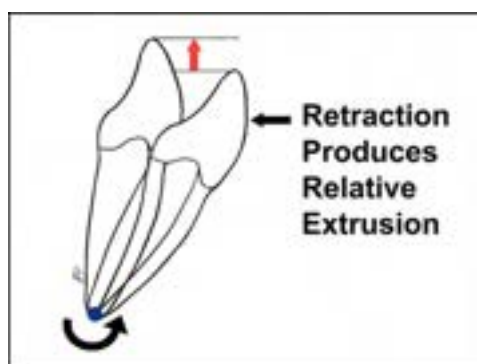


Fig. 19J. A final set of simple refinement aligners were further planned with *lower incisor IPR and retraction for positive, relative incisor extrusion* as shown (transferred to Europe for refinement).

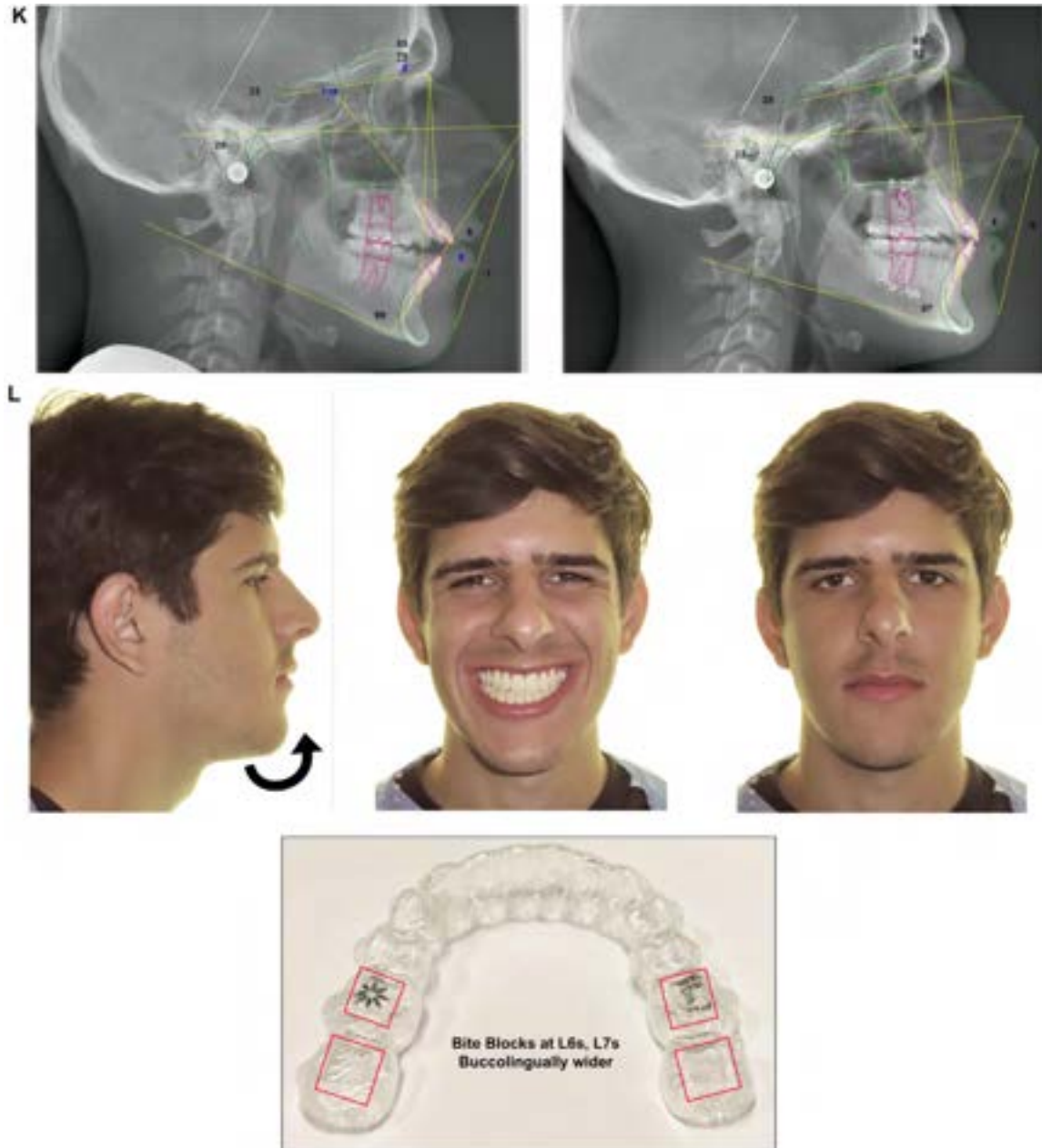


Fig. 19K-L. **K.** Initial and progress lateral cephalometric measurements demonstrate the dentofacial orthopedic effect of aligners and mini-plates with a significant 4.5° counterclockwise autorotation of the mandible that results in a more orthognathic profile. The lower incisor angulation of $IMPA = 93^\circ$ is within the acceptable Tweed-Alexander range of $(90^\circ \pm 3^\circ)$ controlled with IPR and without permitting proclination in the computerized treatment planning for long-term maintenance against relapse. **L.** The profile view confirms the improved mandibular position due to upward and forward mandibular autorotation with good facial harmony and balance. Smile esthetics have improved with posterior intrusion by combining the aligners and skeletal anchorage. In the final stage of treatment, 4mm wide bite blocks at the L6s and L7s may be applied to continue posterior intrusion during finishing since the open bite has been reduced to +10% at the central incisors.

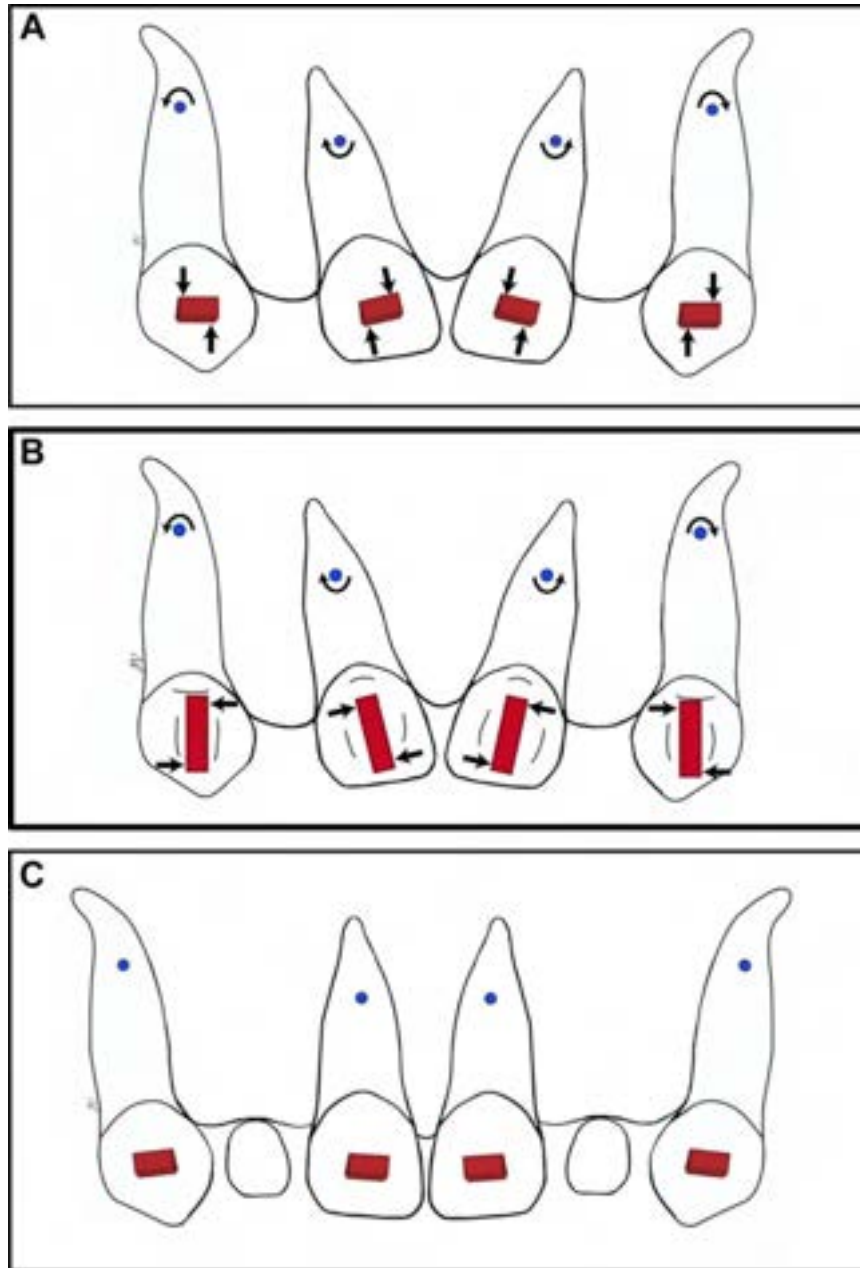


Fig. 20A-C. **A.** Four labial horizontal bonds for esthetics supercorrect roots 200% with forces through a vertical plane. **B.** Added palatal vertical bonds supercorrect 200% also through a horizontal plane compared to **A.** The labial and palatal bonds form a T-Design to maximize the compensation of the roots consistently by 200%. **C.** The labial view shows predictable finishing with the central incisors uprighted (0° angulation) and the canine roots distalized (toward 9° angulation) to provide ample 125% osseous space for implant placement. The vertical bonds on the palatal also continue to be used throughout the treatment for finishing (not shown here). The pontics are narrower mesiodistally reduced a minimum 1.5 mm on each side. The pontics are reduced specifically for the aligner plastic to fit interproximally and for space re-gaining to move the distal of the central incisors and mesial of the canines. This additional interproximal aligner thermoplastic not only assists Stage 1 space regaining, but also the more complex Stage 2 root angulation correction. Thicker labial-palatal interproximal plastic refracts light to camouflage the smaller pontics for acceptable esthetics for short treatment.

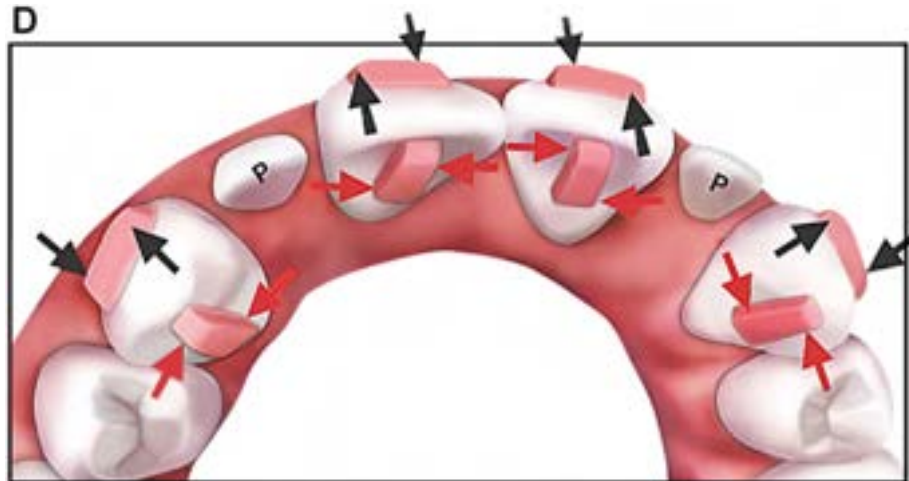


Fig. 20D. Virtual Treatment Planning (VTP) shows labial horizontal bonds, and palatal vertical bonds in the T-Design pattern for effective 200% supercorrection of the roots.



Fig. 21A. A patient age 11 years initially presents with a chief concern for poor smile esthetics related to a severe dental anomaly of hypodontia. There are multiple missing teeth (5 in total with missing lower third molars) including a missing upper right lateral incisor (UR2) with space loss, peg-shaped upper left lateral incisor, missing lower central incisors with over-retained deciduous lower central incisors below. The tooth size discrepancy (TSD) aligner software tool is used for treatment planning of the ideal orthodontic-prosthetic result.

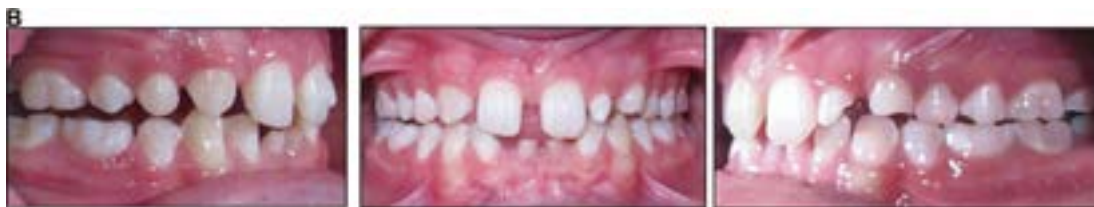

Fig. 21B. A Class II malocclusion is characterized by a large maxillary central incisor diastema due to severe distal drifting of the maxillary central incisors and space loss at the the upper right lateral incisor. In addition, the upper right canine has erupted mesially into the UR2 space. The maxillary left peg-shaped lateral incisor needs to be centered. The lower lateral incisor roots are converging toward the midline and need to be uprighted.

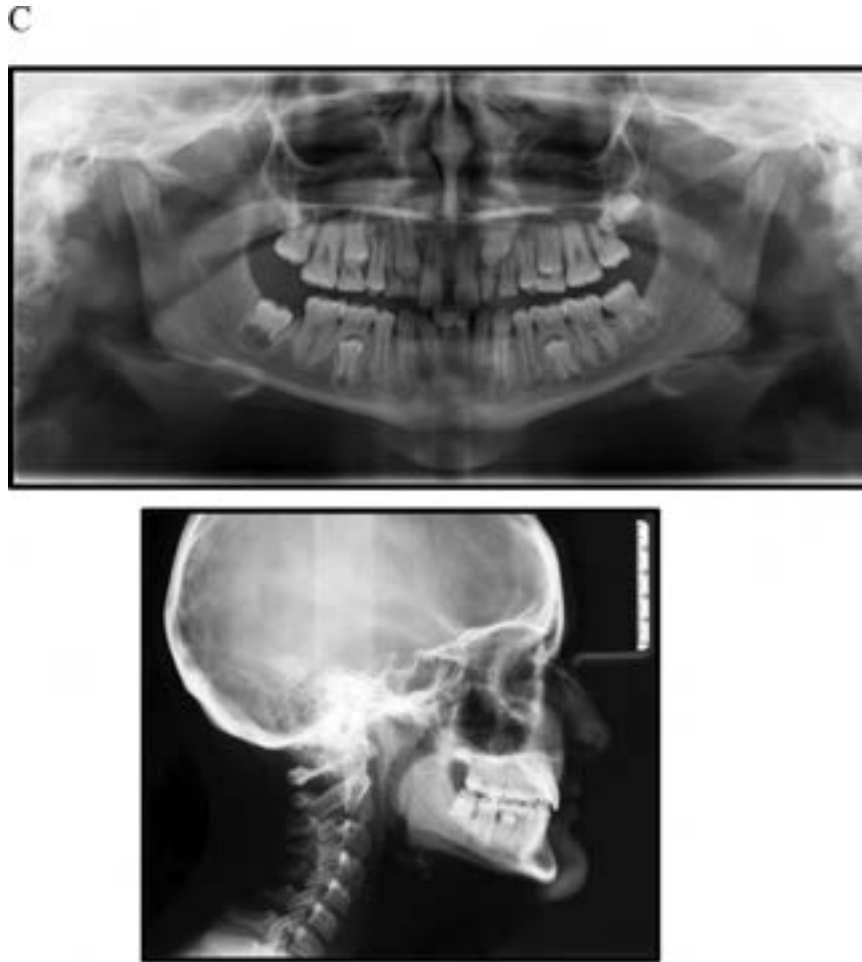

Fig. 21C. The initial panorex (top) shows the significant distal drift of the upper central incisors and moderate mesial drift of the upper canines. Aligner treatment of the upper central incisors is set to parallel the roots, with distal angulation of the upper right and left canine roots. This is in preparation for a temporary Maryland bridge at UR2 (to hold space for future implant) and prosthodontic restoration of the upper left peg-shaped lateral incisor shown. Note, the lower lateral incisor roots are converging toward the mandibular midline that is unfavorable with the axial load of the Maryland bridge that is selected to replace the missing lower central incisors as the temporary restoration in retention. The cephalometric radiograph shows the incisors are also upright over basal bone including the superimposition of the tracings in G.

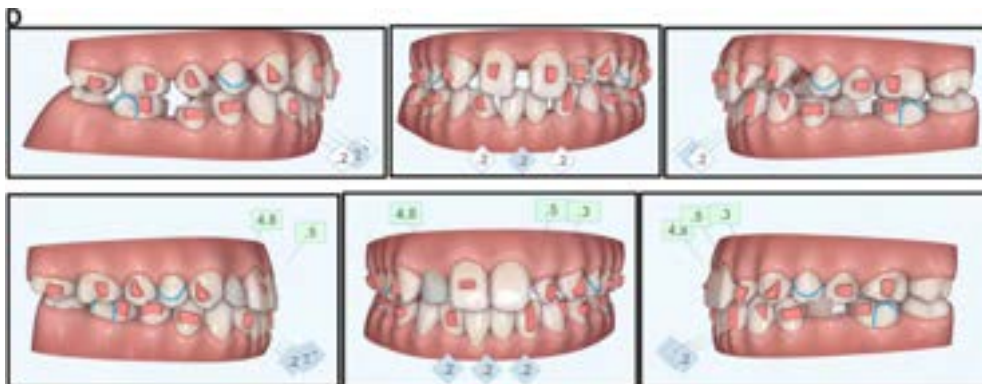

Fig. 21D. Vertical attachments were applied to U1s, L2s for significant uprighting using 46 aligners changed every 7 days. The maxillary canine roots were also distalized with short Class II elastics into Class I for optimum space at the missing UR2, L1s with upright L2 roots, and mesiodistally at peg-shaped lateral incisor UL2 for prosthodontic crown replacement therapy (to include for UR2, LR1, LL1 future implants at age 21).

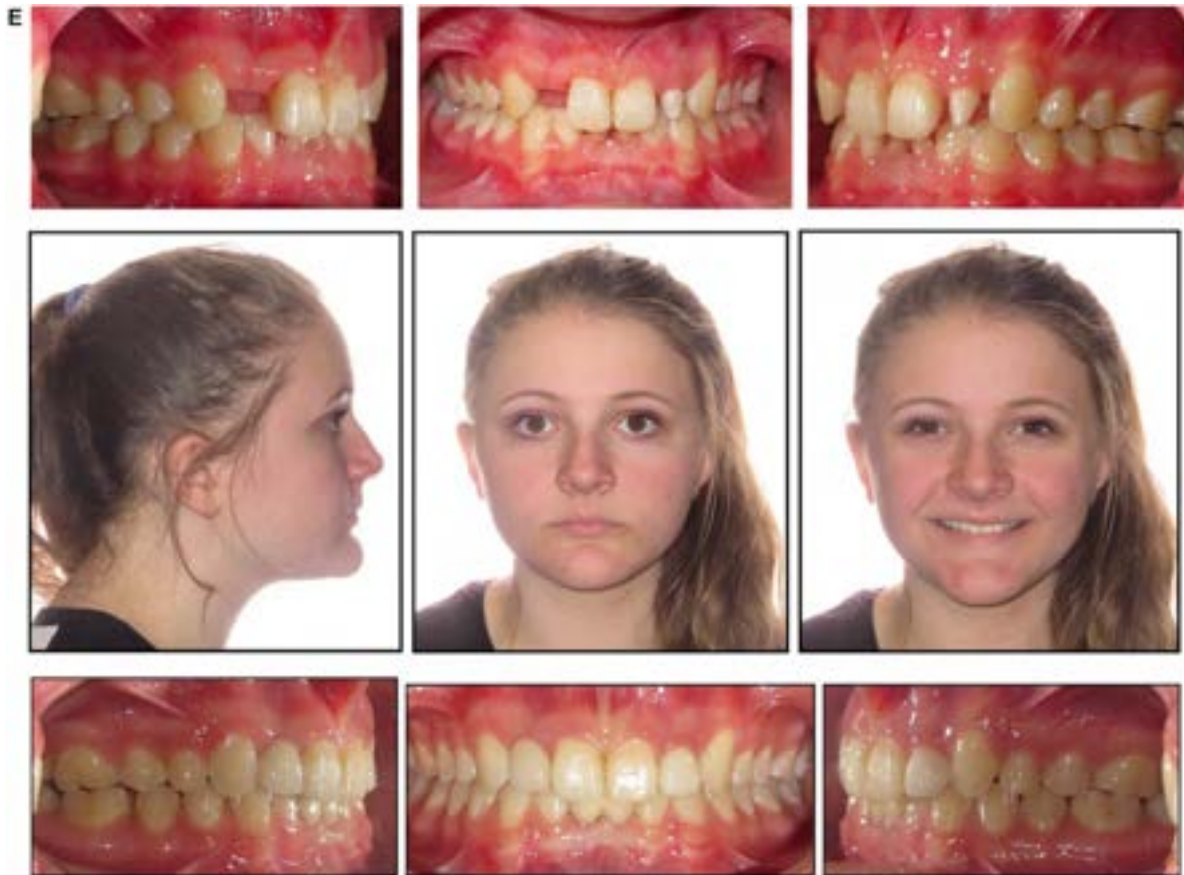

Fig. 21E. A Class I occlusion with the distal root angulations of the U3s, L2s and uprighting of the U1s is shown after 22 aligner refinements and approximately 1.5 years of treatment. At age 15 years, Maryland bridges replace UR2, and L1s and are used for retention until the patient is ready for implants. The UL2 porcelain crown is also inserted.

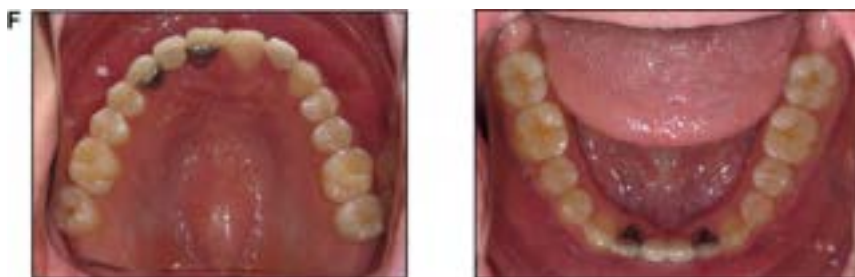

Fig. 21F. Good archforms and general alignment are shown following combined aligner orthodontics with prosthodontic treatment including the crown at the upper left lateral incisor with Maryland bridge replacement of the upper right lateral incisor, and the lower central incisors.

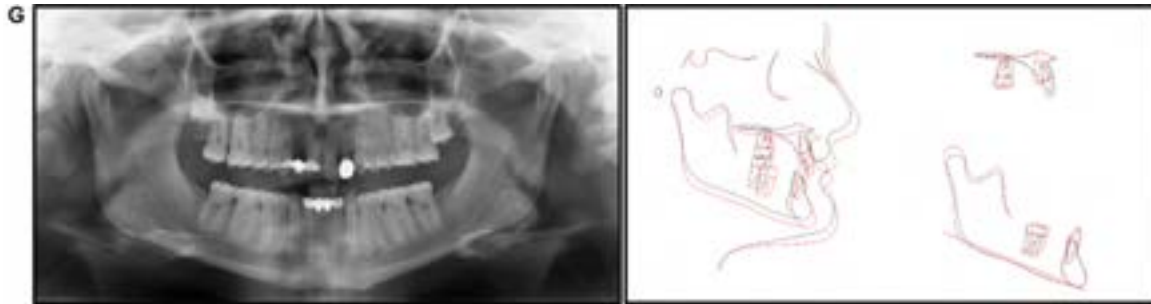


Fig. 21G. The L2s are upright with the upper incisors, IMPA = 92°. The mandible has rotated mildly downward and backward to soften the chin position with good overall facial harmony and balance.

force greater diastema closure than normal, tightening the contacts. Adhere to the IPR values returned digitally and exercise care not to over-disc between the incisors to prevent spacing.

Vertical Maxillary Excess with Excessive Gingival Display (Gummy Smile) and Aligners

An extension of aligner therapy is dentofacial orthopedic intrusion of vertical maxillary excess with a gummy smile (Fig. 22A-E).

Guide #41 Consider TAD-assisted intrusion with aligner incisor intrusion in gummy smiles.

Youth Class III malocclusion with maxillary constriction treated with aligners inverted bite ramps at lower incisors, elastics and torque

As an alternative to rapid maxillary expansion (RME) in young children or adolescents under 16 yrs of age and ideally from 8 to 12 yrs, aligners have been used to expand rapidly by changing aligners that have good retention form. In Stage 1 the

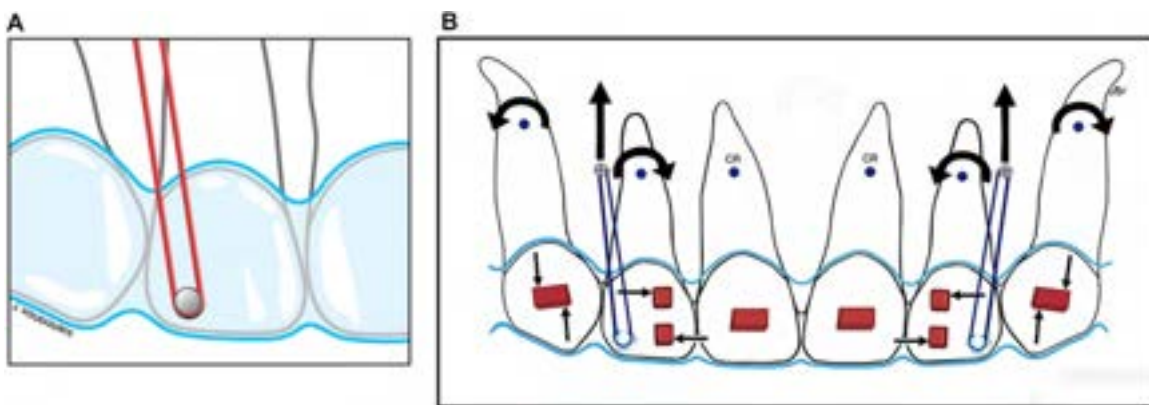


Fig. 22A-B. **A.** Elliptical bonds are planned at the incisal of the U2s, but unfilled, to cut crescent-shaped undercut at the occlusal of the elliptical divot for elastic engagement. **B** shows Stage 1 counterclockwise moments are applied at the UL2 and UR3 roots and clockwise moments at the UR2 and UL3 when the interradicular space is minimal for TADs to produce osseous space. In Stage 2 the U2s are anchored with labial bonds shown to prevent further mesial root movement. The crescent-shaped divots allow for elastic intrusion of the upper incisors in vertical maxillary excess and a gummy smile with aligners (see Figs. 22C, D, E). Crescent-shaped cut-outs on punched divots are also indicated for aligner treatment of impacted canines.

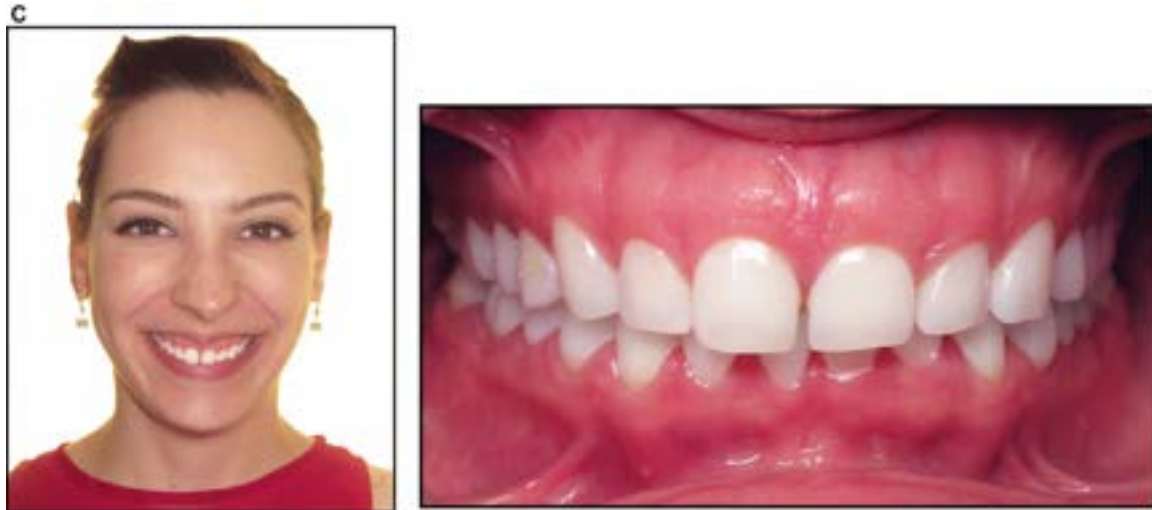

Fig. 22C. A patient presents with an unesthetic gummy smile of over 6 mm gingival exposure from the upper lip line. An acceptable maximum exposure of gingiva esthetically upon smiling is within 2 mm.

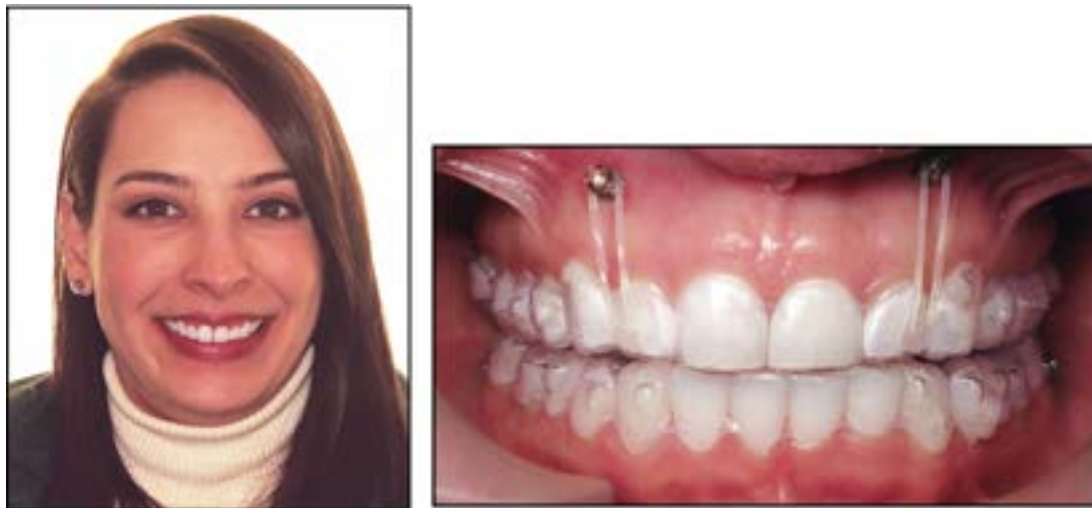

Fig. 22D. Aligner anterior intrusion was used with TADs. Stage 1 includes angulating the roots of the lateral incisors mesially and canine roots distally (Fig. 22B,D,E). In Stage 2, TADs were placed distal of the U2s and as high as possible for a maximum stretch force of an elastic down to crescent-shaped undercuts in the occlusal of the elliptical bond wells as incisal as possible on the U2s. The treatment required a total of 80 aligners changed every 7 days for a total of 20 months of treatment that included two sets of refinements. The maxillary incisors were intruded approximately 3.5 mm using aligners in conjunction with TADs. This combination provided an effective dentofacial orthopedic and esthetic effect for the correction of the gummy smile.

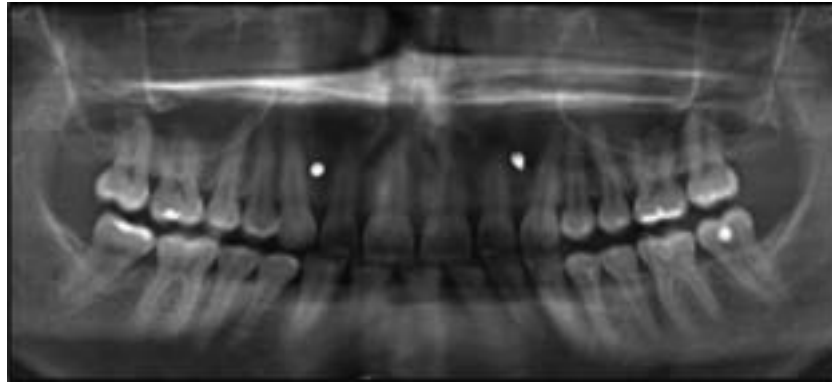


Fig. 22E. The panorex demonstrates the upright position of the upper laterals incisors using clockwise moments of forces on UR2, UL3 and counterclockwise moments of forces on the UL2, UR3 roots. This moves the U2 roots mesially and the U3 roots distally in order to create the space required to insert the two TADs shown as high as possible.

aligners are changed every day for .25 mm of expansion/day for 24–48 days the latter being ideal for up to 12 mm of total expansion. This facilitates rapid midpalatal suture expansion to supercorrect the skeletal crossbite and prepare for natural relapse of about 25-50%. Heavy force aligner adaptation for ideal tracking 23 hrs/day is a key.

A common complication with palatal expansion with aligners, is posterior open bite. This is due to the buccal tipping of the crowns, and extrusion of the palatal cusps of the U7s, U6s and premolars that contact the lower buccal cusps (Fig. 23A). Molars and premolars need double buccal root torque to close the posterior open bite (Fig. 23A,B).

Guide #42 To prevent posterior open bite with expansion, beveled gingival bonds (or OXS, Fig. 1D) are placed

on the buccal of the upper molars. Palatal horizontal beveled attachments are effective when also applied on the upper buccal segments.

In Stage 2 severe, skeletal Class III malocclusion treatment can also be augmented by Reverse-Pull Headgear (RPHG) facemask. Although RPHG is used in youths, adults benefit as well.

Guide #43 Simultaneously in Stages 1 and 2 place bite ramps at the lingual of the four lower incisors to prevent the upper incisors from locking into the lingual of the lower incisors to reduce resistance for Class III correction (Fig. 24B,C). Note, the lower bite ramps are filled with resin.

In Stage 2, during RPHG, if U7s are present also use the bondable buttons at U6s and ceramic bondable button on the lower L3s

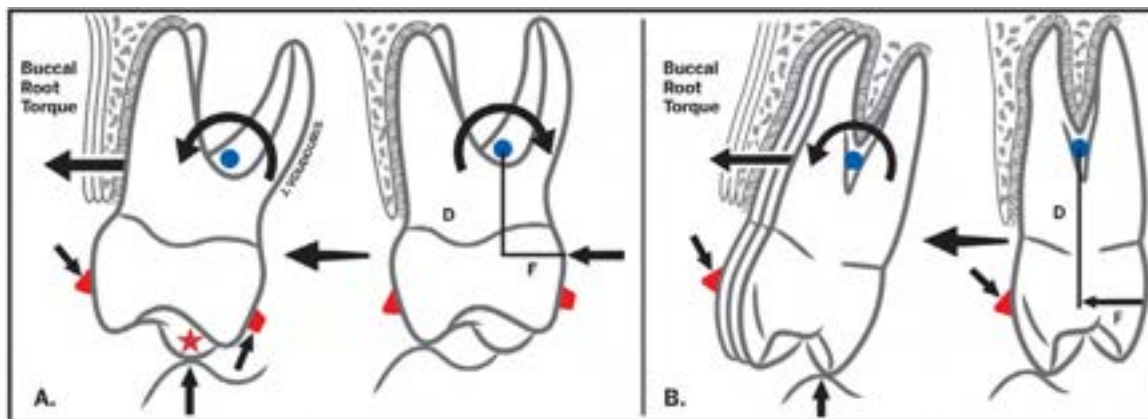


Fig. 23A-B. A. RME force (F) that can also be from a mini-implant supported RME extrudes upper molar palatal cusps (vertical arrow). Beveled gingival bonds are required on the buccal, along with often palatal rectangular bonds to restore buccal root torque. B. Beveled gingival bonds alone at U4s, and U5s work with aligner occlusal forces on the palatal cusps (vertical arrow) to produce 200% supercorrection of buccal root torque following RME. Maxillary expansion is also supercorrected with the palatal cusps of the U5s, U6s in contact with the lower buccal cusps (see Figs. 1D, 23A).

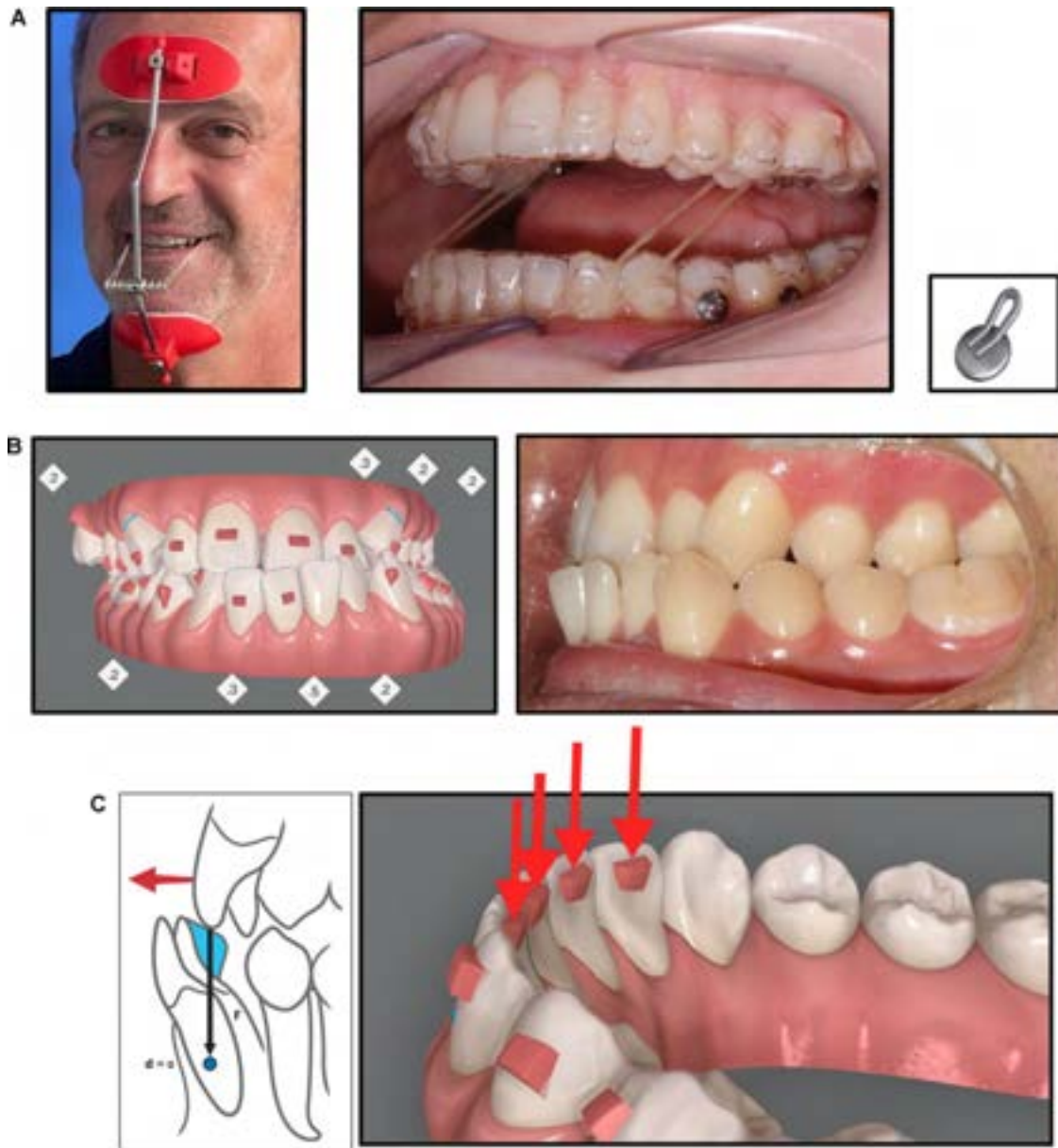


Fig. 24A-C. **A.** Seven steps are applied in skeletal Class III dentofacial orthopedic treatment with aligners, 1) Reverse-pull headgear (RPHG) with Class I medium elastics shown, from U6 cut-outs for ceramic bondable buttons (GC International), or Kaplan hooks (upper right) to advance the maxillary dental arch in an adult 2) Class III intermaxillary elastics are also anchored to the palatal buttons of the upper first molars for protraction and 3) expansion is maintained as the wider portion of the upper arch is advanced forward for coordination (top middle) 4) In youth treatment, after the completion of standard or mini-implant supported RME,¹⁰⁷ upper aligners U5 to 5 work with RPHG and Class I elastics attached above the U3 on looped anterior wire arms extending from the molars of RME to advance skeletal midface deficiency 5) In deep incisor vertical underbite in **B** for example, since aligners have a bias to intrude the posterior buccal segments that tends to resist deep anterior crossbite correction, particularly with lower incisor retraction that also produces extrusion, *lower lingual horizontal bonds are placed at the incisal as inverted lower bite ramps in C.* The ramps are planned simultaneously on the lower incisors with RPHG, Class III elastics and *filled to continue incisor uncoupling when the aligners are removed.* Vertically this disarticulates the incisors to permit the upper incisors to move forward with significantly reduced resistance. 6) Moderate lower incisor IPR for retraction (*that tends to extrude*), with minimal to ideally *no upper IPR* to advance the upper arch 7) Instead, open space for upper anterior alignment and finish with labial crown torque U3 to U3 with 200% supercorrection and Class III elastics. Torque is expressed by doubling the amount needed virtually with flexible aligners in non-surgical, and surgical Class III treatment (Figs. 24 D-L).

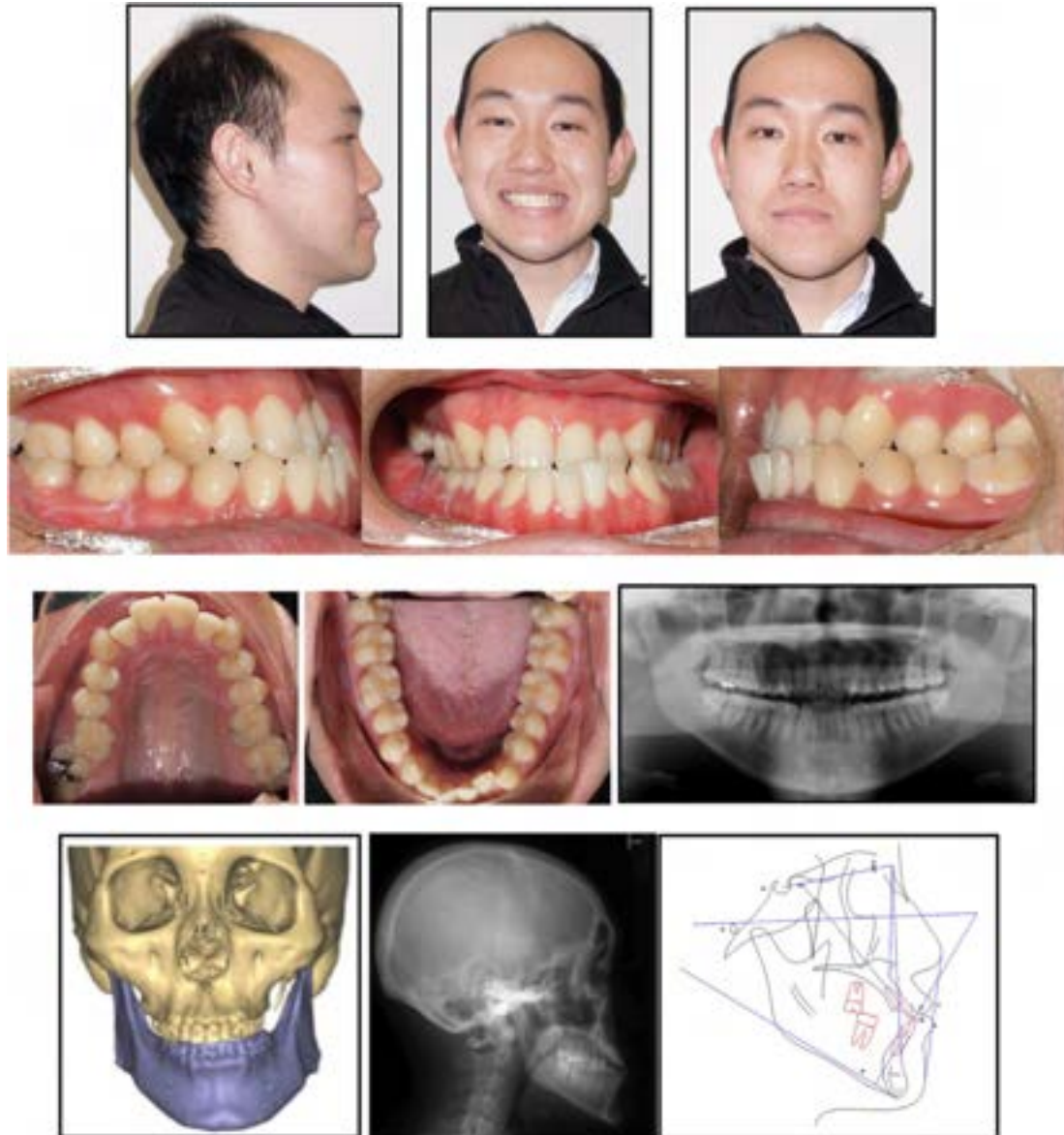


Fig. 24D. Aligner treatment is planned to treat a two-jaw skeletal dysplasia using comprehensive records including CBCT scans. The patient is 29 years of age and presents with a history of childhood trauma to the chin and previous orthodontics. A concave profile type and an acute nasolabial angle of 79° are complicated by severe mandibular asymmetry with the lower midline 5.5 mm to the left of the facial midline. Mandibular hyperplasia is diagnosed where the right ramus and the body of the mandible are longer than the left, with mandibular prognathism despite a steep mandibular plane angle, $FMA = 32^\circ$. Further, maxillary sagittal hypoplasia is present with relative maxillary constriction and an occlusal plane cant on the left side. A full-cusp Class III Subdivision right malocclusion is characterized by proclined upper incisors, -3.5 mm overjet and severe upper and lower crowding. The crowded lower incisors are mildly retroclined with $IMPA = 88^\circ$ and low interincisal angle of 110° . The immediate pre-surgical models are mounted in centric relation for ideal gnathological evaluation, and occlusal adjustment is completed.

directly on the canines for *direct retraction* to continue light Class III elastics. The distal of all 7s need to be well-scanned for the aligner to wrap-around the full distal walls for absolute

anchorage. This takes place with simultaneous, moderate lower IPR to retract the lower incisors.

In Stage 2, simultaneous lower incisor retraction additionally extrudes the lower incisors

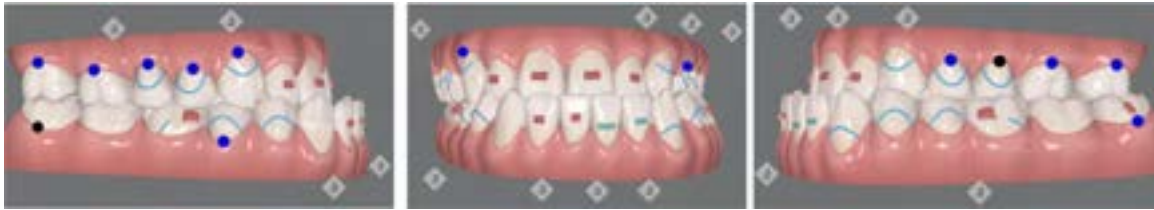


Fig. 24E. Aligner decompensation for 10 months and 35 aligners changed q7wks pre-surgically uprights the upper and lower incisors, with upper expansion and Class II elastics. Button cut-outs are shown for the stage preceding the surgical jump needed for stabilization during surgery and intermaxillary elastics post-surgically.

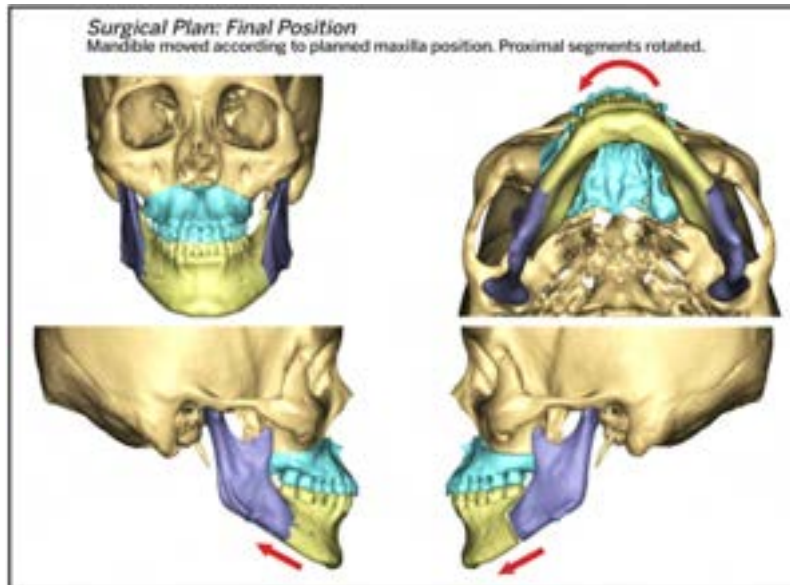


Fig. 24F. A LeFort 1 maxillary advancement is planned to correct the occlusal cant and move the wider portion of the upper arch forward for relative crossbite correction. Mandibular asymmetry surgery to the right of the facial midline is simulated to correct the skeletal Class III dysplasia that includes the left condyle and fossa.

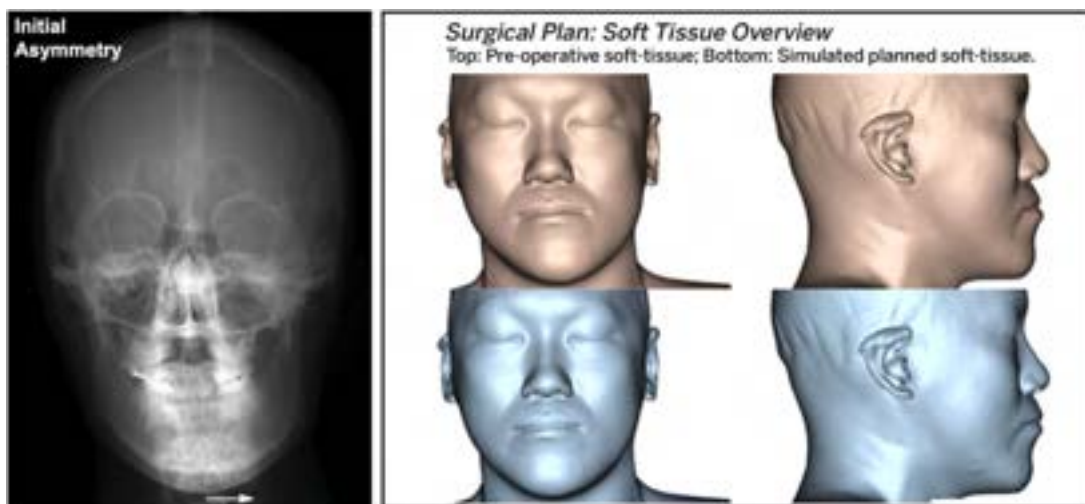


Fig. 24G. The initial, severe facial mandibular asymmetry is to the left of the facial midline with midface deficiency and an acute nasolabial angle (top). The soft tissue changes are simulated following the mandibular asymmetry surgery and maxillary advancement that balances the profile (in blue) and occlusion in Fig. 24I.

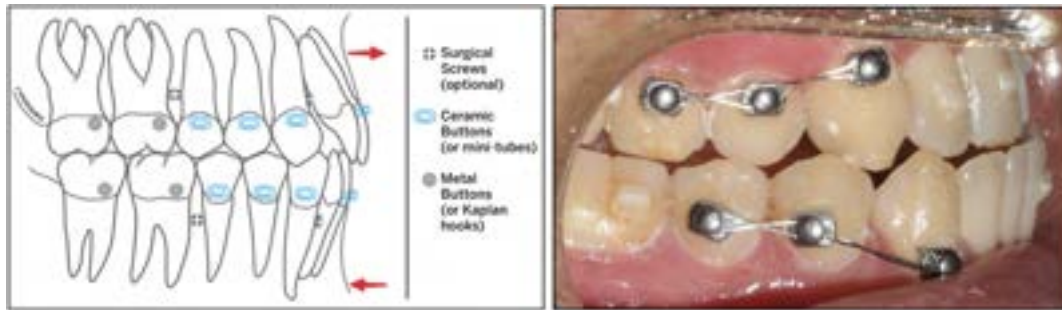


Fig. 24H. Following aligner Stage 1 alignment and leveling, buttons are placed pre-surgically for elastics and temporarily ligated to each other in the event of a debond. Four TADs illustrated are optional, and not required currently. The patient is scanned 3 months after the surgery for the post-surgical finishing stage and 20 aligner refinements with Class III elastics on the right side applied to align the upper canines. The midline is corrected, however, the tipped upper canines need further alignment. The patient is scanned for another 13 aligners refinements with cut-outs for CAD-designed tunnel attachments made chairside to allow NiTi wires to assist the aligners to move the upper canine roots to their planned positions. Mild IPR was also necessary between the lower incisors to increase the anterior overbite.

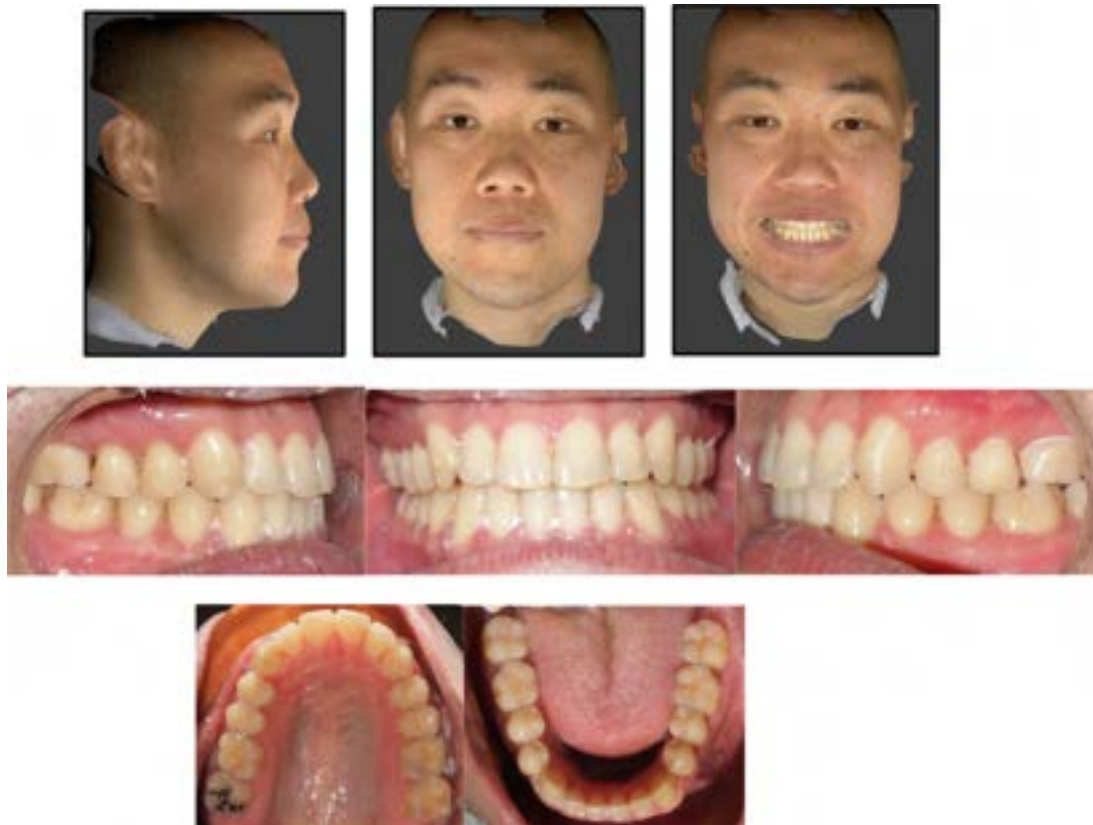

Fig. 24I. A comparison of post-surgical facial images with the initial photoimages in Fig. 24D demonstrates the improved facial harmony and balance with the maxillary LeFort 1 maxillary advancement and differential mandibular setback. A well intercuspated occlusion with coordinated midlines is achieved using post-surgical Stage 2 aligner treatment. In summary, there were 33 pre-surgical aligners, 20 post-surgical aligners with one set of 13 refinement aligners.

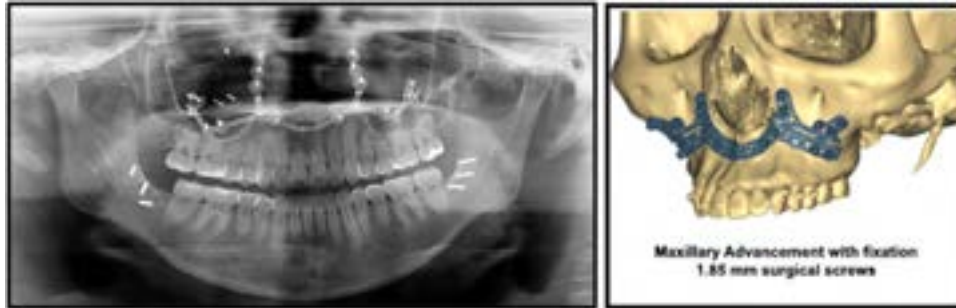


Fig. 24J. Good skeletal relationships are established following two-jaw surgery with good overall root integrity and following Stage 2 aligner therapy for leveling, aligning and detailing post-surgically.

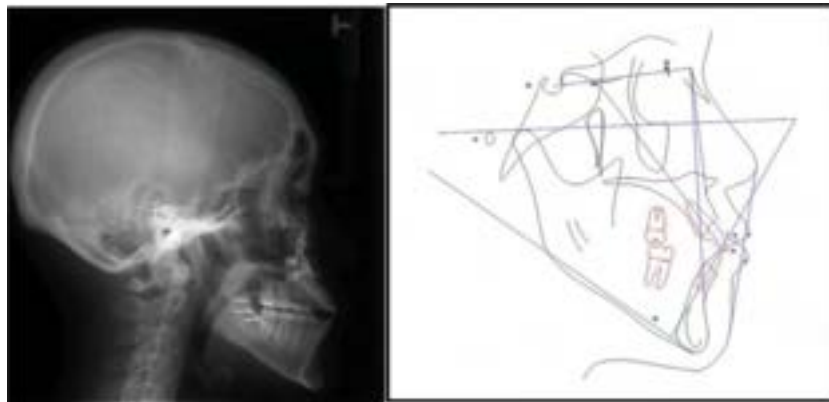


Fig. 24K. The Class III molar relationship has been corrected, and the upper incisors were advanced with the maxillary LeFort 1 advancement surgery. The mandible was rotated downward and backward with a FMA =37.5°, and the interincisal angle changed positively to 114° from the initial 110°.

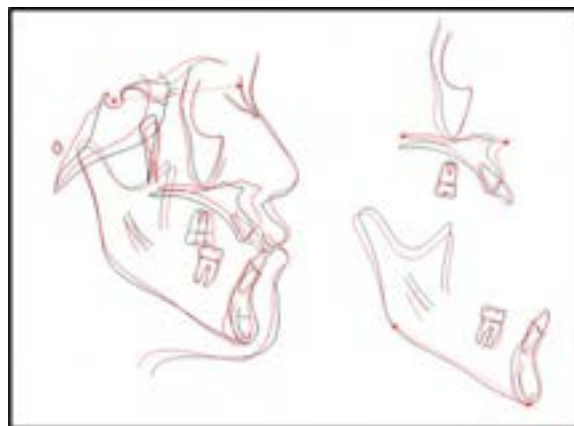


Fig. 24L. The mandible was differentially setback to the right of the facial midline with the asymmetry surgery and the maxilla was advanced approximately 8 mm that also corrected the cant of the occlusal plane.

effectively in conjunction with upper incisor labial crown torque in Class III malocclusions when there is initially, minimal overbite. This

secures the anterior occlusion and initiates anterior guidance that maintains the early correction of the Class III malocclusion.

Aligner clinical pearls: Invisalign® MA

Guide #44 Mandibular retrognathism is common in orthodontics and does not generally improve spontaneously.¹⁰⁸ To treat severe mandibular retrognathism in growing children a mandibular advancer (MA) is applied at the time of peak pubertal growth. The reason is systematic review with meta-analysis has shown peak timing increases the amount of mandibular growth modification by approximately two-fold.^{109,110} The peak mandibular growth is assessed by taking the carpal radiograph in the lateral cephalogram machine, that is a medical standard.

Guide #45 There are generally 3 Stages of MA: Pre-MA, MA and Post-MA. The Pre-MA stage includes leveling and aligning both dental arches to upright the roots of the dentition in preparation for the MA stage.

Guide #46 The U6, U5, L6, L5 bonds are removed to place the Precision Wings™ (PW).

Guide #47 In the MA Stage 2, the mandible is advanced progressively using two triangular Precision Wings^{111,112} 2 mm every 2 months. This produces 1) condylar displacement and de-compression for endochondral bone modification at the condyle 2) stretch of the retrodiskal tissue pulls on the glenoid fossa for appositional bone formation 3) that radiates by transduction of forces to the articular eminence. These are the factors associated with the skeletal bone modifications mainly since the lateral pterygoid and masseter EMG muscle activities are reduced.¹¹³⁻¹¹⁵ This is because the Precision Wings™ open the vertical dimension and bite approximately 7 mm to hold the mandible forward edge-to-edge +2mm and prevent backward escape during closure (Fig. 25A,B).

Guide #48 Class II elastics, 3/16" 4.5 oz are maintained post-MA.

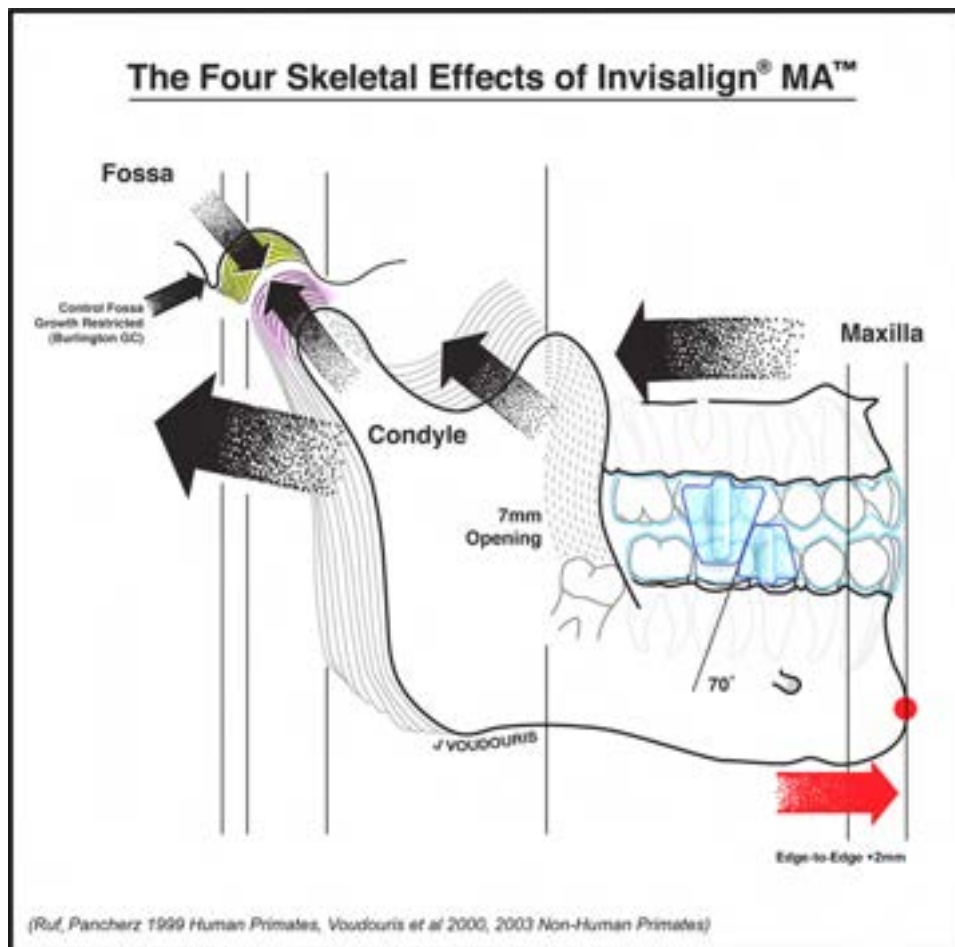
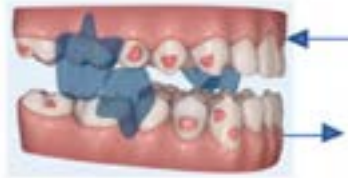

Fig. 25A. Invisalign® Class II Mandibular Advancer with Precision Wings™ positioned +2 mm beyond the incisor edge-to-edge position is the end goal on the virtual treatment plan with progressive advancement to anticipate a significant amount of relapse. As the condyle is displaced and decompressed from the fossa the retrodiskal tissues stretch and pull on the glenoid fossa for bone formation in both areas shown (yellow and red).

12 Evidence-based Contributions of Class II Md Advancers

(J Voudouris, University of Toronto, Faculty of Dentistry, Instructor Graduate Orthodontic Program in Orthodontics)



Four Skeletal

1. Maxillary Restriction
2. Mandibular Growth Modification ($\geq 2\text{mm}$ Cozza et al)*
3. Glenoid Fossa Modification (UToronto, often missed)
4. Glenoid Fossa Restriction (Burlington GC, missed)

Four Dental

5. Maxillary molars forward and down movement restricted
6. Maxillary incisors retracted
7. Mandibular molars mesialized
8. Mandibular incisors proclined**

Four Supplemental Clinical Contributions

9. Counter-clockwise mandibular rotation is facilitated via intrusion of upper molars
10. Differential Eruption of lower buccal segments
11. Correction of 2 Viscoelastic Tissue obstructions, lower lip moved from lingual of upper incisors to labial, and 4 lower incisors unlocked from palatal tissues in deep overbite
12. Maxillary Expansion accommodates wider portion of advanced mandibular arch removing dental interferences and lateral functional mandibular shifts for uninterrupted condyle-fossa modifications***

*Perinetti et al, in standard, systematic review with meta analysis demonstrated when MA is properly timed for pubertal growth, using a simple cephal radiograph, mandibular modification is approximately double (3-4mm). It is important to note added glenoid fossa modifications need to also be measured using the Pancharz Analysis, not Co-Gn. Reasons some do not see benefits of MAs is, treatment is started in the pre- or post-pubertal growth phase, and they need to have a full understanding of the evidence of the 12 contributions.

**Lower incisor proclination with heavy Class II elastics alone is unstable. The indication for Class II MAs is skeletal changes.

***There is no evidence from systematic reviews, however, that maxillary expansion permits greater mandibular modification (foot-in-slipper). EMG muscle activity is also reduced with correction of vertical dimension (UT) in Class II deep bite for stable interincisal vertical stops and stable occlusal coupling to maintain the skeletal and other contributions

Fig. 25B. Twelve contributions of Class II Mandibular Advancers (MAs).

JVoudouris Supercorrection Prescription	
Level	Skeletal and Dental Movements
110%	1. Rotations $\geq 15^\circ$ 2. Midlines 3. Local molar intrusion 4. Local molar uprighting 5. Root uprighting during mild space consolidation 6. Super Class I molar overcorrection with maxillary segmental distalization ^{7,9,53} and 7. Invisalign® MA™, with a Supercorrected edge-to-edge ^{10-11,12} + 2mm anterior bite registration with L1, L2 - 6° clinical lingual root torque*
150%	1. Progressive Posterior Extrusion (PPE) in moderate, deep overbite < 50% ^{73,76} 2. Youth aligner rapid palatal expansion with U6 palatal to L6 buccal cusp contact
200%	1. PPE when in deep overbite $\geq 50\%$ 2. Progressive Posterior Intrusion (PPI) in open bite > 0% 3. Torque* for incisors, ¹⁹ molars 4. Lateral incisor root convergences 5. Upper incisor angulation 6. 200%+ Canine M-D root uprighting ¹⁶ 7. 200%+ Extraction root uprighting 8. 200%+ Incisor intrusion ⁵ 9. 200%+ Incisor extrusion ¹⁶
Aligner average supercorrections are systematized guidelines based on scientific evidence-based efficacy, and clinical studies including systematic reviews to reach best possible practices. ^{1-3,14,17,18} Derived from 3 Orders of Predictable Tooth Movements.	

Table I. Differential supercorrection virtual prescription for simple to highly complex malocclusions.

Summary: Supercorrection Prescription and Biomechanics

A) Aligners have highly sophisticated, multi-layer, semi-elastic properties for biological tooth movement in simple treatments.⁴⁸ However, in highly complex malocclusions that include dentofacial orthopedics the virtual treatment plan set-up requires a more powerful differential supercorrection prescription (Table I). This significantly alters the shapes of the successive aligners to reach the ideal facial and dental clinical goals (Table II) with the added objective of minimizing refinements. The three levels of the supercorrection prescription are based on an extensive review of several scientific investigations on aligner efficacy. They included the highest quality investigations of systematic reviews,^{2,3,18} with meta-analysis,¹⁷ a randomized trial,¹ and several cohort studies on effectiveness as a foundation for best practice guidelines.

B) This is particularly relevant in severe overbite and open bite treatment since the essential loading of supercorrections into the virtual treatment plan assures quality clinical outcomes consistently and overcomes the multiple refinements.

C) Six basic attachment geometries were also classified for more confident planning that

included the recently introduced aligner multi-directional forces with different magnitudes of force (Invisalign®, G8™). Collectively this assisted aligner biomechanics that were practical for clinical applications and problem solving such as, working out U2 tracking issues, torque, intrusion, extrusion, or angulation management.

D) Aligners with a multi-directional, multi-force intrusion and tipping bias were shown clinically to be the appliance of choice for adult molar intrusion and molar uprighting.

E) It was demonstrated that aligner applications could produce a higher level of dentofacial orthopedic effects with, and without the assistance of TADs or mini-plates.

F) Significant neuromuscular hyperactivity resisted aligner posterior extrusion in deep overbite. Conversely, muscle hypoactivity improved with regular Chewie muscle exercises for posterior intrusion that corrected severe open bite. This included recommendations that attempted to control the etiology of allergic or physical nasopharyngeal obstruction that assisted aligners. Nine interdisciplinary orthodontic-periodontic-surgical and prosthodontic patient treatments from a collaboration with seven aligner experts were presented demonstrating:

JCV Prescription							
Maxillary		Torq°	Ang°	Mandibular		Torq°	Ang°
Central		+12	+4	Anterior*		0	+2
Lateral		+9	+8	Cuspid		0	+3
Cuspid		0	+7	1st Bicuspoid		-7	0
		0	+9	2nd Bicuspoid		-9	0
1st and 2nd Bicuspoid		-7	0	1st Molar		-30	0
1st Molar		-7	0	2nd Molar		-11	0
2nd Molar		-7	0				
*For U6 anti-rotation +34° and for U7 = 9°				*For MA treatment lower anterior torque = 0°			

Table II. Ideal JCV clinical prescription* goals with aligners include L2 distal root angulation, reduced lower progressive buccal root torque for improved curve of Wilson and reduced upper canine angulation (*moderated MBT).

Seven Dentofacial Orthopedic Effects with Aligner Treatment:

1. Youth Class II maxillary segmental distalization for 4-6 months with lower passive aligner (1 mm thick) and Class II elastics have demonstrated mild skeletal restriction at the maxilla and a mild increase in the vertical dimension (Kim-Berman, et al). In Stage II, continued Class II elastics previously trivialized, appear to be associated with correction of lower lip impingement and skeletal retrognathism.
2. *Aligners demonstrate desirable posterior intrusion for correction of a cant of the occlusal plane.* This includes curved aligners at the anterior for serpentine intrusion with a unilateral mini-plate (TAD) that has applications in youth, teen and adult skeletal asymmetry.
3. Aligner posterior intrusion is facilitated with bilateral mini-plates or TADs in four quadrants for effective buccal segment intrusion in severe skeletal open bite for counter-clockwise mandibular autorotation (also demonstrated without TADs).
4. Aligner anterior intrusion works synergistically with anterior TADs and elastics in Vertical Maxillary Excess (VME) with a gummy smile.
5. Invisalign® MA™ for Class II dysplasia including skeletal mandibular retrognathism has four potential skeletal effects that are cumulatively greater than zero in retention including maxillary restriction, mandibular condyle and temporal glenoid fossa modifications, with restriction of downward and backward fossa growth (Burlington Growth Center). Maxillary expansion is needed to coordinate the advanced wider portion of the lower arch. A key with deep overbite is the MA provides viscoelastic balance by a) unlocking the lower incisors impinging within the palatal tissues b) reversing the lower lip forces pushing anteriorly against the palatal of UIs and c) on the incisal edges of the UIs. The removal of

the soft tissue forces can lead to more unrestricted, mandibular growth.

6. Youth lower aligners with new inverted lower bite ramps that are *filled* to effectively uncouple skeletal Class III malocclusion when aligners are worn or removed with deep incisor overbite for maxillary advancement with mini-implant supported RME and buccal extension arms with loop ends.
7. Reverse-pull headgear in conjunction with aligners for skeletal Class III midface deficiency treatment in youths, teens and adults.

Six New Aligner Techniques:

- a. New aligner force-matrix systems using multi-directional forces and different magnitudes of force for differential moments of forces, are like a heat-map for individual dental units (Invisalign® G8™). The *dominant* moment of force and moment of a couple are applied in aligner biomechanics.
- b. New clear, curved-up maxillary segmental distalizer with mid-hook.
- c. Aligner Tongue Trainers virtually treatment planned and inserted *unfilled*, and punctured on the palatal and lingual of all 12 anterior teeth addresses the strongest set of multi-directional muscles of the tongue during anterior positioning in open bite.
- d. Two lateral crescent-shaped cut-outs on the buccal of aligners for triangular-pattern elastics to TAD in open bite.
- e. Crescent-shaped cut-outs on occlusal of *unfilled* divot protrusions locally at the labial-incisal of upper lateral incisors for intrusion of anteriors that has applications for impacted upper canines.
- f. Inverted bite ramps *filled* to uncouple Class III malocclusion with anterior deep bite.

Three orders of predictable movements were determined from the literature review and were the basis for the Aligner Supercorrection Prescription of 110%, 150% and 200%:

Orders of Predictable Aligner Movements*

First Order 1° of Predictability: Effective with Mild Supercorrection

1. **Buccolingual, M-D movements:** Incisors,²⁰ buccal segments, and minor spacing
2. **Incisor de-rotation.** Mild to moderate rotations <15°, while other movements below were previously thought impossible²⁰
3. **Posterior intrusion, extrusion:** Aligner occlusal coverage has a posterior intrusion tendency that is assisted by muscle forces and indicated for local molar intrusion, and local molar tipping that is highly predictable as demonstrated in this review. In deep bites, bite ramps are effective for buccal segment extrusion.
4. **Uncontrolled tipping:** Uprighting proclined L1s with relative extrusion can also be controlled by aligner coverage.¹² Severe incisor proclination with aligner tends to produce relative intrusion (U2 gaps and loss of aligner tracking).
5. **Molar distalization:** Effective with maxillary segmental distalizers (MSD) in 4-6 months.¹⁹ This is also possible without MSD, with mean 21 months for aligner distalization of U6s and U7s.

Second Order 2° of Predictability: Effective with Moderate Supercorrection

6. **TAD-Assisted incisor intrusion:** In VME with gummy smile, C-T Technique.
7. **TAD-Assisted molar intrusion:** In severe open bites with C-T Technique, in conjunction with progressive posterior intrusion.
8. **Invisalign® MA™** highly effective with patient care of Precision Wings™ and compliance.^{60,110-112}
9. **Reverse-pull headgear:** Advances maxilla and upper arch with aligner and RME buccal extension arms soldered to upper first molar bands. Includes Class II headgear.
10. **Mini-implant assisted RME:** Expansion for constriction and crossbites, with aligners.

Third Order 3° of Predictability: Effective with High Supercorrection

11. **Controlled angulation:** Diverging L2 roots away from midline (T-Design attachments),

uprighting roots in missing U2s, closing moderate to severe spacing, root uprighting adjacent to extraction spaces (at U3s with G6™ and G8™).

12. **Torque:** Incisor torque,¹⁹ and molar buccal root torque.
13. **Premolar extrusion:** In deep overbite $\geq 50\%$ with clenching and hyperactive muscle forces when directed on aligner coverage, extrusions meets resistance⁷⁴⁻⁷⁷
14. **De-rotation of round or short crowns:** Moving round premolars or canines requires lingual attachments for added retention, and for short crowns^{19,36}
15. **Incisor intrusion:** In deep overbite it is challenging to produce and to retain intrusion specifically for upper and lower central incisors that are found to be less accurate.^{7,15}
16. **Incisor extrusion:** Highly challenging with semi-elastic thermoplastic particularly in open bite with downward-backward mandibular growth, and includes mesial-distal tipping of all canines that is complex due to root length¹⁶

*Depends on age, gender, muscle activity, airway, bone metabolism and density, severity of crowding, position in the arch, size and shape of crown and root(s), and other factors.

Compensating for unexpected upper lateral incisor gaps: three steps chairside

A) *Guide #49 Apply Clenchy™ holding 10 seconds to seat aligner over bond with 10-20 repetitions, 3-times/day until aligners are adapted. Repeat this exercise chairside with a facial mirror. This prevents undesirable intrusion especially of the U2 (Figs. 2A, 3).*

B) If an incisal gap persists, a high-speed bur may be used to mildly round the gingival bond edges with a small reduction in the thickness of the bond if necessary to help further fit the aligner over the U2s when control is lost. Patients are instructed to save all aligners since they may need to also go back and apply the previous aligner to try to recover the U2 tracking. However, *once a U2 gap is formed it is challenging for a patient to recover. See effective Step C (avoids re-scanning that takes time for remakes of aligners to return).*

C) *Guide #50 For chronic, lack of fitting at the U2s two buttons can be bonded to uncontrolled U2s, one*

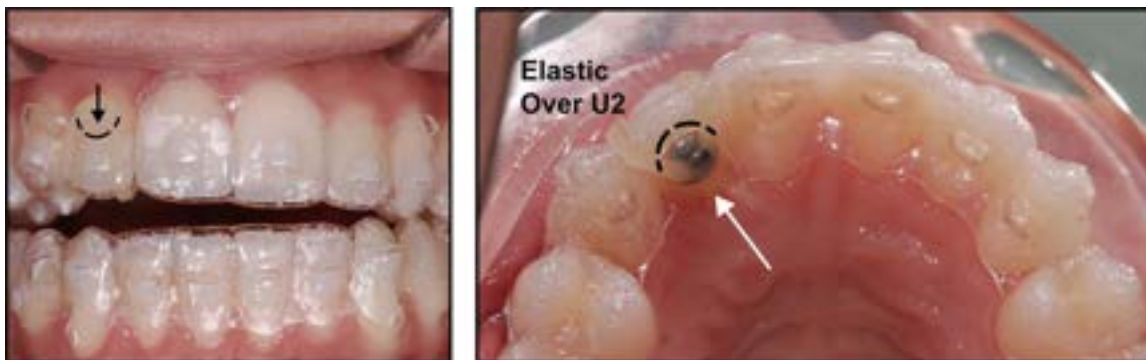


Fig. 26. The Elastic Wrap Technique with ceramic bondable button (GC International®) on labial and button on palatal with associated cut-out domes (dotted). The elastic wrap is placed as shown from the labial ceramic bondable button over the aligner to the palatal metal button to re-extrude the UR2.

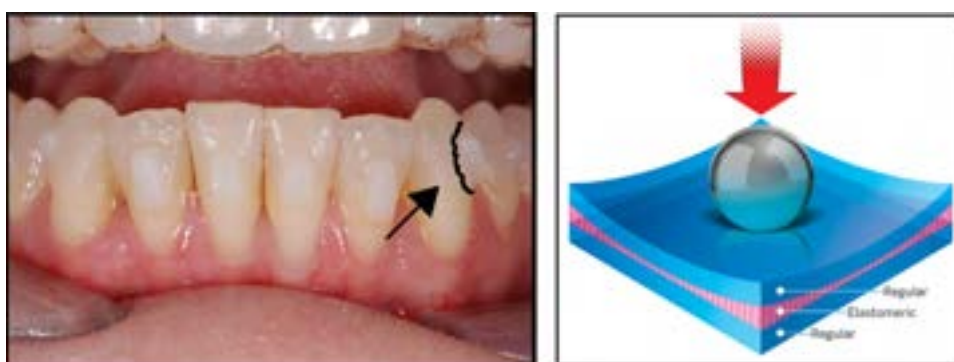


Fig. 27A-B. **A.** Etch only around the bond area to prevent flash. For bond removal, cut horizontally through the bond near the enamel with high-speed flame bur to undermine the resin and pop off labial face. Use a resin scaler plier to crumble the surface resin. This reduces the use of a high-speed and the amount of bio-aerosol with resin dust. **B.** The 0.75" aligner material generally has 3-5 layers, including a middle elastomeric thermoplastic layer that rotates and skews reversibly, sandwiched between two harder clear plastic layers to assist U2 tracking.

ceramic at the labial and one palatal for placement of an elastic "wrap" (Fig. 26). The aligners need to have dome cut-outs at the labial and palatal to allow the fit of the buttons. A moderate force 3/16", 4.5 oz elastic is worn by the patient over the U2 to extrude it into the aligner (Fig. 26).

Efficiency of timing: bonds and IPR

Bond attachments are presented at consultation and resin is pre-loaded prior to the patient's next appointment (aligner perforation is generally not recommended over bond well).

*Guide #51 On Day 1 of aligner insertion complete all bond applications and all interproximal reduction (IPR) if possible for comfort and efficiency.**

Guide #52 For ideal expression of the bonds use a ball burnisher on the occlusal and Hollenback carver at the gingival to squeeze excess 3M ESPE Filtek Supreme Ultra Flowable resin.¹¹ Check excess resin flash is

removed from the enamel on all 4 sides of bonds, including the occlusal with a scaler, or high-speed flame bur, that reduces gaps and improves tracking (Fig. 27 A,B).

*Guide #53 *When IPR is not required on Day 1, stage IPR to be coordinated at same intervals of e.g. 6-12 aligner sets (every 6, 12, 18, 24, etc) for efficiency.¹² In addition, place simple "Hold" stickers on the package of the last set of e.g. 6 sets of aligners to remind patient not to miss their appointment for their mid-treatment IPR. The last aligner provided to the patient divided by the total number of aligners is always recorded at each appointment in the electronic chart e.g. 12/24.*

Future Investigations

Effective clinical innovations such as some new aligner advancements can appear similar to Angle's edgewise bracket in 1929, or certainly titanium implants by Brånemark, since they may

occasionally precede scientific investigations. This is true for the serendipitous and dramatic medical discovery of penicillin. However, these are exceptions, and scientific data is essential to verify further clinical applications. We are reminded of the first promising effects of thalidomide in medicine. This new treatment required much greater and more rigorous scientific investigation to avoid the resulting effects. The initial sowing of these several new aligner supercorrections and other innovations in dentofacial orthopedics are intended to harvest the many scientific studies that will surely follow in the years ahead.

*Invisalign® G5™ G6™ G7™ G8™ the optimized extrusion support attachments™ power ridges™, Invisalign MA™, precision wings™ and Vivera™ are registered trademarks of Align Technology, San Jose, California, USA, JVBarre® 4D™ and Aligner Tongue Trainers (ATTs) are registered trademarks of Spartan Orthodontics, Toronto, Ontario, Canada, Clenchy™ is a trademark of IDM Tooling, Carrollton, Texas, USA, Essix™ and Chewies™ (aligner seaters, tray seaters) are trademarks of Dentsply Sirona® Raintree, Sarasota, Florida, USA, Precision Aligner Buttons™ and CS-2000™ fixed springs are trademarks of Dynaflex®, St. Louis, Missouri, USA, Ceramic bondable buttons and metal bondable buttons are from GC Orthodontics®, Alsip, Illinois, USA, Pul™ tool is a trademark of PUL Technologies, San Francisco, California, USA, ESPE Filtek Supreme Ultra Flowable™ resin is a trademark of 3M Orthodontics®, St. Paul, Minnesota, USA, Innobyte™ is a trademark of Kube Innovations®, Montreal, Quebec, Canada. All rights reserved.

This paper is dedicated to the memory of Dr. Sheldon Peck at the Harvard School of Dental Medicine and to his inspiration, Dr. Edward Hartley Angle.

References

- Al-Nadawi M, Kravitz ND, Hansa I, Makki L, Ferguson DJ, Vaid NR. Effect of clear aligner wear protocol on the efficacy of tooth movement: a randomized clinical trial. *Angle Orthod.* 2021;91:157–163.
- Rossini G, Parrini S, Castrolorio T, Deregibus A, Debernardi CL. Efficacy of clear aligners in controlling orthodontic tooth movement: a systematic review. *Angle Orthod.* 2015;85:881–889. <https://doi.org/10.2319/061614-436.1>.
- Lagravère M, Flores-Mir C. The treatment effects of Invisalign orthodontic aligners: a systematic review. *J Am Dent Assoc.* 2005;136:1724–1729. <https://doi.org/10.14219/jada.archive.2005.0117>.
- Lindauer SJ, Isaacson RJ. One-couple orthodontic appliance systems. *Semin Orthod.* 1995;1:12–24.
- Isaacson RJ, Rebellato J. Two-couple orthodontic appliance systems: torquing arches. *Semin Orthod.* 1995;1:31–36.
- Pedersen E, Andersen K, Gjessing PE. Electronic determination of centers of rotation produced by orthodontic force systems. *Eur J Orthod.* 1990;12:272–280.
- Charalampakis O, Iliadi A, Ueno H, Oliver DR, Kim KB. Accuracy of clear aligners: a retrospective study of patients who needed refinement. *Am J Orthod Dentofac Orthop.* 2018;154:47–54.
- Buschang PH, Ross M, Shaw SG, Crosby D, Campbell PM. Predicted and actual end-of-treatment occlusion produced with aligner therapy. *Angle Orthod.* 2015;85:723–727. <https://doi.org/10.2319/043014-311.1>.
- Grünheid T, Loh C, Larson BE. How accurate is Invisalign in nonextraction cases? Are predicted tooth positions achieved? *Angle Orthod.* 2017;87:809–815. <https://doi.org/10.2319/022717-147.1>.
- Larson BE, Vaubel CJ, Grünheid T. Effectiveness of computer-assisted orthodontic treatment technology to achieve predicted outcomes. *Angle Orthod.* 2013;83:557–562.
- Hansa I, Semaan SJ, Vaid NR. Clinical outcomes and patient perspectives of dental monitoring GoLive with Invisalign – a retrospective cohort study. *Prog Orthod.* 2020;21:1–7.
- Hansa I, Semaan SJ, Vaid NR, Ferguson DJ. Remote monitoring and “tele-orthodontics”: concept, scope and applications. *Semin Orthod.* 2018;24:470–481.
- Borda AF, Garfinkle JS, Covell DA, Wang M, Doyle L, Sedgley CM. Outcome assessment of orthodontic clear aligner vs fixed appliance treatment in a teenage population with mild malocclusions. *Angle Orthod.* 2020;90:485–490. <https://doi.org/10.2319/122919-844.1>.
- Robertson L, Kaur H, Fagundes NCF, Romanyk D, Major P, Flores Mir C. Effectiveness of clear aligner therapy for orthodontic treatment: a systematic review. *Orthod Craniofac Res.* 2020;23:133–142.
- Haouili N, Kravitz ND, Vaid NR, Ferguson DJ, Makki L. Has Invisalign improved? A prospective follow-up study on the efficacy of tooth movement with Invisalign. *Am J Orthod Dentofac Orthop.* 2020;158:420–425.
- Kravitz ND, Kusnoto B, BeGole E, Obrez A, Agran B. How well does Invisalign work? A prospective clinical study evaluating the efficacy of tooth movement with Invisalign. *Am J Orthod Dentofac Orthop.* 2009;135:27–35.
- Papageorgiou SN, Koletsi D, Iliadi A, Peltomaki T, Eliades T. Treatment outcome with orthodontic aligners and fixed appliances: a systematic review with meta-analyses. *Eur J Orthod.* 2019;42:1–13.
- Papadimitriou A, Mousoulea S, Gkantidis N, Kloukos D. Clinical effectiveness of Invisalign orthodontic treatment: a systematic review. *Prog Orthod.* 2018;19:37.
- Simon M, Keilig L, Schwarze J, Jung BA, Bourauel C. Treatment outcome and efficacy of an aligner technique – regarding incisor torque, premolar derotation and molar distalization. *BMC Oral Health.* 2014;14:1–7. <https://doi.org/10.1186/1472-6831-14-68>.
- Brezniak N. The clear plastic appliance: a biomechanical point of view. *Angle Orthod.*

- 2008;78:381–382. [10.2319/0003-3219\(2008\)078\[0381:TCPA\]2.0.CO;2](https://doi.org/10.2319/0003-3219(2008)078[0381:TCPA]2.0.CO;2).
21. Buschang PH, Shaw SG, Ross M, Crosby D, Campbell PM. Comparative time efficiency of aligner therapy and conventional edgewise braces. *Angle Orthod.* 2014;84:391–396. <https://doi.org/10.2319/062113-466>.
 22. Pavoni C, Lione R, Lagana G, Cozza P. Self-ligating versus Invisalign: analysis of dentoalveolar effects. *Ann Stomatol (Roma)*. 2011;II:23–27.
 23. Gu J, Tang J, Skulski B, Fields H, Beck F, Firestone A, Kim DG, Deguchi T. Evaluation of Invisalign treatment effectiveness and efficiency compared with conventional fixed appliances using the Peer Assessment Rating index. *Am J Orthod Dentofac Orthop.* 2007;151:259–266. [10.1016/j.ajodo.2016.06.041](https://doi.org/10.1016/j.ajodo.2016.06.041).
 24. Djeu G, Shelton C, Maganzini A. Outcome assessment of Invisalign and traditional orthodontic treatment compared with the American Board of Orthodontics objective grading system. *Am J Orthod Dentofac Orthop.* 2005;128:292–298.
 25. Gao L, Wichelhaus A. Forces and moments delivered by the PET-G aligner to a maxillary central incisor for palatal tipping and intrusion. *Angle Orthod.* 2017;87:534–541. <https://doi.org/10.2319/090216-666.1>.
 26. Simon M, Keilig L, Schwarze J, Jung BA, Bourauel C. Forces and moments generated by removable thermoplastic aligners: incisor torque, premolar derotation, and molar distalization. *Am J Orthod Dentofac Orthop.* 2014;145:728–736. <https://doi.org/10.1016/j.ajodo.2014.03.015>.
 27. Lombardo L, Martines E, Mazzanti V, Arreghini A, Mollica F, Siciliani G. Stress relaxation properties of four orthodontic aligner materials: a 24-hour in vitro study. *Angle Orthod.* 2016;87:11–18. <https://doi.org/10.2319/113015-813.1>.
 28. Vardimon AD, Robbins D, Brosh T. In-vivo von Mises strains during Invisalign treatment. *Am J Orthod Dentofac Orthop.* 2010;138:399–409.
 29. Morton J, Derakhshan M, Kaza S, Li C. Design of the Invisalign system performance. *Semin Orthod.* 2016;23:3–11. <https://doi.org/10.1053/j.sodo.2016.10.001>.
 30. Bollen AM, Huang G, King G, Hujoel P, Ma T. Activation time and material stiffness of sequential removable orthodontic appliances. Part I: ability to complete treatment. *Am J Orthod Dentofac Orthop.* 2003;124:496–501.
 31. Clements KM, Bollen AM, Huang G, King G, Hujoel P, Ma T. Activation time and material stiffness of sequential removable orthodontic appliances. Part 2: dental improvements. *Am J Orthod Dentofac Orthop.* 2003;124:502–508.
 32. Gomez JP, Peña FM, Martínez V, Giraldo DC, Cardona CI. Initial force systems during bodily tooth movement with plastic aligners and composite attachments: a three-dimensional finite element analysis. *Angle Orthod.* 2015;85:454–460. <https://doi.org/10.2319/050714-330.1>. Epub 2014 Sep 2. PMID: 25181252.
 33. Moshiri M, Kravitz ND, Nicozisis J, Miller S. Invisalign eighth-generation features for deep-bite correction and posterior arch expansion. *Semin Orthod.* 2021;27:175–178.
 34. Eliades T, Papageorgiou SN, Ireland AJ. The use of attachments in aligner treatment: analyzing the “innovation” of expanding the use of acid etching-mediated bonding of composites to enamel and its consequences. *Am J Orthod Dentofac Orthop.* 2020;158:166–174. <https://doi.org/10.1016/j.ajodo.2020.04.008>.
 35. Dasy H, Dasy AG, Rózsa N, Lee H, Kwak JH. Effects of variable attachment shapes and aligner material on aligner retention. *Angle Orthod.* 2015;85:934–940. <https://doi.org/10.2319/091014-637.1>.
 36. Cortona A, Rossini G, Parrini S, Deregibus A, Castorflorio T. Clear aligner orthodontic therapy of rotated mandibular round-shaped teeth: a finite element study. *Angle Orthod.* 2020;90:247–254. <https://doi.org/10.2319/020719-86.1>.
 37. Cai Y, He B, Yang X, Yao J. Optimization of configuration of attachment in tooth translation with transparent tooth correction by appropriate moment-to-force ratios: biomechanical analysis. *Biomed Mater Eng.* 2015;26:507–517. <https://doi.org/10.3233/BME-151340>. PMID: 26406042.
 38. Voudouris JC. Tongue star 2 (TS2)-System for rapid open bite closure. *Ortho Int Mag Orthod.* 2017;2:11–15.
 39. Baldwin D, King G, Ramsay DS, Huang G, Bollen A. Activation time and material stiffness of sequential removable orthodontic appliances. Part 3: premolar extraction patients. *Am J Orthod Dentofac Orthop.* 2008;133:837–845.
 40. Thai JK, Araujo E, McCray J, Schneider PP, Kim KB. Esthetic perception of clear aligner therapy attachments using eye-tracking technology. *Am J Orth Dentofac Orthop.* 2020;158:400–409. <https://doi.org/10.1016/j.ajodo.2019.09.014>.
 41. Williams R. Eliminating lower retention. *J Clin Orthod.* 1985;19:342–349.
 42. Kalemaj Z, Levrini L. Quantitative evaluation of implemented interproximal enamel reduction during aligner therapy: a prospective observational study. *Angle Orthod.* 2021;91:61–66. <https://doi.org/10.2319/040920-272.1>.
 43. Kravitz ND, Kusnoto B, Agran B, Viana G. Influence of attachments and interproximal reduction on the accuracy of canine rotation with Invisalign®. A prospective clinical study. *Angle Orthod.* 2008;78:682–687.
 44. Grünheid T, Gaalaas S, Hamdan H, Larson BE. Effect of clear aligner therapy on the buccolingual inclination of mandibular canines and the intercanine distance. *Angle Orthod.* 2016;86:10–16. <https://doi.org/10.2319/012615-59.1>.
 45. Liu W, Shao J, Li S. Volumetric cone-beam computed tomography evaluation and risk factor analysis of external apical root resorption with clear aligner therapy. *Angle Orthod.* 2021;91:597–603. <https://doi.org/10.2319/111820-943.1>.
 46. Weltman B, Vig K, Fields H, Shanker S, Kaizar E. Root resorption associated with orthodontic tooth movement: a systematic review. *Am J Orthod and Dentofac Orthop.* 2010;137:462–476. <https://doi.org/10.1016/j.ajodo.2009.06.021>.
 47. Aman C, Azevedo B, Bednar E, Nicholson E, Nicholson K, Scarfe WC. Apical root resorption during orthodontic treatment with clear aligners: a retrospective study using cone-beam computed tomography. *Am J Orth Dentofac Orthop.* 2018;153:842–851. <https://doi.org/10.1016/j.ajodo.2017.10.026>.

48. Weinstein S, Haack DC, Morris LY, Snyder BB, Attaway HE. On an equilibrium theory of tooth position. *Angle Orthod.* 1963;33:1–26.
49. Haynes S. The distribution of overjet and overbite in English children aged 11–12 years. *Dent Pract Dent Rec.* 1972;22:380–383.
50. Björk A. Variability and age changes in overjet and overbite. *Am J Orthod.* 1953;39:779–801.
51. Björk A. Variations in the growth pattern of the human mandible. Longitudinal radiographic study by the implant method. *J Dent Res.* 1963;42:400.
52. Voudouris JC, Gaveglia V, Poulos JJ. BiTurbo2 (BT2) system for rapid deep bite overbite correction. *Ortho Int Mag Orthod.* 2017;1:30–36.
53. Voudouris JC, Voudouris JD. New JVBarre maxillary segmental distalizer and BiTurbo2 system for greater aesthetics, effective and efficient skeletal Class II treatment: control of canine over-extrusion and bodily maxillary molar distalisation. *Ortho Int Mag Orthod.* 2019;4:14–19.
54. Kim-Berman H, McNamara Jr JA, Lints JP, McMullen C, Franchi L. Treatment effects of the Carriere Motion 3D appliance for the correction of Class II malocclusion in adolescents. *Angle Orthod.* 2019;89:839–846.
55. Polur I, Peck S. Orthodontic elastics: Is some tightening needed? *Angle Orthod.* 2010;80:988–989.
56. Adams CD, Meikle MC, Norwick KW, Turpin DL. Dentofacial remodelling produced by intermaxillary forces in Macaca mulatta. *Arch Oral Biol.* 1972;17:1519–1535. [https://doi.org/10.1016/0003-9969\(72\)90039-8](https://doi.org/10.1016/0003-9969(72)90039-8). PMID: 4630218.
57. Voudouris JC, Woodside DG, Altuna G, Kuftinec MM, Angelopoulos G, Borque PJ. Condyle-fossa modifications and muscle interactions during Herbst treatment, Part 1: New technological methods. *Am J Orthod Dentofac Orthop.* 2003;123:604–613.
58. Voudouris JC, Woodside DG, Altuna G, Angelopoulos G, Bourque PJ, Yamin Lacouture C. Condyle-fossa modifications and muscle interactions during Herbst treatment, Part 2: Results and conclusions. *Am J Orthod Dentofac Orthop.* 2003;124:13–29.
59. Ruf S, Pancherz H. Temporomandibular joint remodeling in adolescents and young adults during Herbst treatment: a prospective longitudinal magnetic resonance imaging and cephalometric radiographic investigation. *Am J Orthod Dentofac Orthop.* 1999;155:607–618.
60. Voudouris JC, Kuftinec MM. Improved clinical use of Twin-block and Herbst as a result of radiating viscoelastic tissue forces on the condyle and fossa in treatment and long-term retention: Growth relativity. *Am J Orthod Dentofac Orthop.* 2000;117:247–266.
61. Weislander L. Intensive treatment of severe Class II malocclusions with a headgear-Herbst appliance in the early mixed dentition. *Am J Orthod.* 1984;86:1–13.
62. Weislander L. Long-term effect of treatment with the headgear-Herbst appliance in the early mixed dentition. Stability or relapse? *Am J Orthod.* 1993;104:319–329.
63. Ravera S, Castrolforio T, Garino F, Daher S, Cugliari G, Deregibus A. Maxillary molar distalization with aligners in adult patients: a multicenter retrospective study. *Prog Orthod.* 2016;17:1–9. <https://doi.org/10.1186/s40510-016-0126-0>.
64. Franchi L, Baccetti T. Prediction of individual mandibular changes induced by functional jaw orthopedics followed by fixed appliances in Class II patients. *Angle Orthod.* 2006;76:950–954.
65. Bjork A, Skieller V. Facial development and tooth eruption: an implant study at the age of puberty. *Am J Orthod.* 1972;62:339–383.
66. Storey AT. Physiology of a changing vertical dimension. *J Prosthet Dent.* 1962;12:912–921.
67. Manns A, Miralles R, Guerrero F. The changes in electrical activity of the postural muscles of the mandible upon varying the vertical dimension. *J Prosthet Dent.* 1981;45:438–445.
68. Rugh JD, Drago CJ. Vertical dimension: a study of clinical rest position and jaw muscle activity. *J Prosthet Dent.* 1981;45:70–75.
69. Engel G, Damerell JM, McAlpine J, Walters R. Treatment of deep-bite cases. *Am J Orthod.* 1980;77:1–13.
70. Ingervall B, Minder C. Correlation between maximum bite force and facial morphology in children. *Angle Orthod.* 1997;67:415–422.
71. Lione R, Franchi L, Noviello A, Bollero P, Fanucci E, Cozza P. Three-dimensional evaluation of masseter muscle in different vertical facial patterns: a cross-sectional study in growing children. *Ultrasonic imaging.* 2013;35:307–317. [10.1177/0161734613502468](https://doi.org/10.1177/0161734613502468).
72. Kiliaridis S. Masticatory muscle influence on craniofacial growth. *Acta Odontol Scand.* 1995;53:196–202.
73. Proffit WR, Fields HW, Nixon WL. Occlusal forces in normal-and long-face adults. *J Dent Res.* 1983;62:566–571.
74. Blundell H, Weir T, Kerr B, Freer E. Predictability of overbite control with the Invisalign appliance. *Am J Orthod Dentofac Orthop.* 2021;160:725–731. <https://doi.org/10.1016/j.ajodo.2020.06.042>.
75. Kravitz ND, Moshiri M, Nicozisis J, Miller S. Mechanical considerations for deep-bite correction with aligners. *Semin Orthod.* 2020;26:134–138.
76. Khosravi R, Cohanim B, Hujoel P, Daher S, Neal M, Liu W, Huang G. Management of overbite with the Invisalign appliance. *Am J Orthod Dentofac Orthop.* 2017;151:691–699.
77. Giancotti A, Mampieri G, Greco M. Correction of deep bite in adults using the Invisalign system. *J Clin Orthod.* 2008;42:719–726.
78. Berg R. Stability of deep overbite correction. *Eur J Orthod.* 1983;5:75–83.
79. Hirschfelder U, Fleischer-Peters A. The functional treatment of deep bite – the results of a long-term study. *Fortschr Kiefer orthoped.* 1992;53:313–321.
80. Hirschfelder U, Hertrich K. The treatment of deep bite in adults. *Fortschr Kiefer orthop.* 1990;51:36–43.
81. Voudouris JC, Cameron CG, Poulos JJ, Sanovic S. The anterior bite plane nightguard for neuromuscular anterior de-programming. *J Clin Orthod.* 2008;42:84–97.
82. Blake M, Bibby K. Retention and stability: a review of the literature. *Am J Orthod.* 1998;114:299–306.
83. Mills RJE. The long term results of proclination of lower incisors. *Br Dent J.* 1966;120:355–363.
84. Houston WJB, Edler R. Long-term stability of the lower labial segment relative to the A-Pog line. *Eur J Orthod.* 1990;12:302–310.

85. McCauley DR. The cuspid and its function in retention. *Am J Orthod.* 1944;30:196–205.
86. Riedel RA. A review of the retention problem. *Angle Orthod.* 1960;30:179–194.
87. Årtun J, Krogstad O, Little RM. Stability of mandibular incisors following excessive proclination. A study in adults with surgically treated mandibular prognathism. *Angle Orthod.* 1990;60:99–106.
88. Peck S, Peck H. Crown dimensions and mandibular incisor alignment. *Angle Orthod.* 1972;42:148–153.
89. Dugoni SA, Lee JS, Varela J, Dugoni A. Early mixed dentition treatment: postretention evaluation of stability and relapse. *Angle Orthod.* 1995;65:311–320.
90. Vig K. Nasal obstruction and facial growth: The strength of evidence for clinical assumptions. *Am J Orthod Dentofac Orthop.* 1998;113:603–611. [10.1016/S0889-5406\(98\)70219-7](https://doi.org/10.1016/S0889-5406(98)70219-7).
91. Proffit WR, Fields HW, Sarver DM. The etiology of orthodontic problems. *Contemporary Orthodontics.* St. Louis: Elsevier Mosby; 2013:133–146.
92. Tomer BS, Harvold EP. Primate experiments on mandibular growth direction. *Am J Orthod.* 1982;82:114.
93. Fields HW, Warren DW, Black K, Phillips CL. Relationship between vertical dentofacial morphology and respiration in adolescents. *Am J Orthod Dentofac Orthop.* 1991;99:147–154. [https://doi.org/10.1016/0889-5406\(91\)70117-F](https://doi.org/10.1016/0889-5406(91)70117-F). PMID: 1990824.
94. Linder-Aronson S, Adenoids. Their effect on mode of breathing and nasal airflow and their relationship to characteristics of the facial skeleton and the dentition. A biometric, rhino-manometric and cephalometro-radiographic study on children with and without adenoids. *Acta Otolaryngol Suppl.* 1970;265:1–132.
95. Woodside DG, Linder-Aronson S, Lundstrom A, McWilliam J. Mandibular and maxillary growth after changed mode of breathing. *Am J Orthod Dentofac Orthop.* 1991;100:1–18.
96. Friedman F. *Sleep Apnea and Snoring: Surgical and Non-Surgical Therapy.* Edinburgh: Sanders-Elsevier; 2009.
97. Subtelny JD, Sakuda M. Open-bite: diagnosis and treatment. *Am J Orthod.* 1964;50:337–358. [https://doi.org/10.1016/0002-9416\(64\)90175-7](https://doi.org/10.1016/0002-9416(64)90175-7).
98. Proffit W. Moderate Nonskeletal Problems in Preadolescent Children. In: Proffit W, Fields HW, Sarver DM, eds. *Contemporary Orthodontics.* Elsevier Mosby; 2019:395–415.
99. Ngan P, Fields HW. Open bite: a review of etiology and management. *Pediatr Dentist.* 1997;19:91–98. Mar-Apr PMID: 9106869.
100. Huang GJ, Baltuck C, Funkhouser E, Wang C, Todoki L, Finkleman S, Shapiro P, Khosravi R, Ko J, Greenlee G, De Jesus-Vinas J, Vermette M, Larson M, Dolce C, Kau CH, Harnick D. The national dental practice-based research network adult anterior open bite study: treatment recommendations and their association with patient and practitioner characteristics. *Am J Orthod.* 2020;156:312–325.
101. Todoki LS, Finkleman SA, Funkhouser E, Greenlee G, Choi K, Ko J, Wang C, Shapiro P, Khosravi R, Baltuck C, Allareddy V, Dolce C, Kau CH, Shin K, De Jesus-Vinas J, Vermette M, Jolley C. The national dental practice-based research network collaborative group, and Huang GJ. The national dental practice-based research network adult anterior open bite study: treatment success. *Am J Orthod.* 2020;158:137–150.
102. Lou T, Tran J, Castroflorio T, Tassi A, Cioffi I. Evaluation of masticatory muscle response to clear aligner therapy using ambulatory electromyographic recording. *Am J Orthod Dentofac Orthop.* 2021;159:25–33. <https://doi.org/10.1016/j.ajodo.2020.08.012>.
103. Woodside DG, Linder-Aronson S. Progressive increase in lower anterior face height and the use of posterior occlusal bite block in its management. editor. In: Graber LW, ed. *Orthodontics: State of the Art, Essence of the Science.* St. Louis, Mo: C.V. Mosby Co.; 1986:200–221.
104. Dénes B, Lazzarotto B, Bresin A, Kiliaridis S. Effect of different masticatory functional demands on the 3D mandibular condyle morphology of growing rats using posterior bite-blocks. *Eur J Orthod.* 2017;40:1–5.
105. Lione R, Kiliaridis S, Novello A, Franchi L, Antonarakis G, Cozza P. Evaluation of masseter muscles in relation to treatment with removable bite-blocks in dolichofacial growing subjects: a prospective controlled study. *Am J Orthod Dentofac Orthop.* 2017;151:1058–1064. [10.1016/j.ajodo.2016.10.035](https://doi.org/10.1016/j.ajodo.2016.10.035).
106. Pinho T, Mariana S. Skeletal open bite treated with clear aligners and miniscrews. *Am J Orthod Dentofac Orthop.* 2021;159:224–233. <https://doi.org/10.1016/j.ajodo.2019.07.020>.
107. Wilmes B, Nienkemper M, Drescher D. Application and effectiveness of a mini-implant- and tooth-borne rapid palatal expansion device: the hybrid hyrax. *World J Orthod.* 2010;11:323–330.
108. Yoon SS, Chung CH. Comparison of craniofacial growth of untreated Class I and Class II girls from ages 9 to 18 years: a longitudinal study. *Am J Orthod Dentofac Orthop.* 2015;147:190–196.
109. Perinetti G, Primozi J, Franchi L, Contardo L. Treatment effects of removable functional appliances in prepubertal and pubertal Class II patients: a systematic review and meta-analysis of controlled studies. *PLOS One.* 2015;10:1–35.
110. Voudouris JC, Poulos JJ, Schismenos C, Argyropoulos C. Invisalign mandibular advancers and tetrahedron 3D facial analysis in dentofacial orthopedics: 10 rules. *J Clin Orthod.* 2018;52:134–147.
111. Giancotti A, Cozza P, Mampieri G. Aligners and mandibular advancement: a comprehensive option for phase I treatment of Class II, division 1 cases. *J Clin Orthod.* 2020;54:513–524.
112. Glaser B. *Invisalign Treatment with Mandibular Advancement- A Review of the North American study.* American Association of Orthodontics presentation; 2019. Los Angeles, California. (submitted for publication).
113. Sessle BJ, Woodside DG, Bourque PJ, Gurza S, Powell G, Voudouris J, Metaxas A, Altuna G. Effect of functional appliances on jaw muscle activity. *Am J Orthod Dentofac Orthop.* 1990;98:222–230.
114. Auf der Maur HJ. Electromyographic recordings of the lateral pterygoid muscle in activator treatment of Class II division I malocclusion cases. *Eur J Orthod.* 1980;2:161–171.
115. Antonarakis G, Kiliaridis S. The effects of Class II functional appliance treatment are influenced by the masticatory muscle functional capacity. *Iran J Orthod.* 2018;13:1–7. [10.5812/ijo.6703](https://doi.org/10.5812/ijo.6703).