

Does age influence deep overbite correction with Invisalign? A prospective study evaluating mandibular incisor intrusion in adolescents vs adults

Neal D. Kravitz^a; Ismaeel Hansa^b; Nikhilesh R. Vaid^c; Mazyar Moshiri^d; Samar M. Adel^e

ABSTRACT

Objective: To compare the accuracy of mandibular incisor intrusion with Invisalign (Align Technology, Santa Clara, Calif) in adolescents to that in adults.

Materials and Methods: This prospective clinical study included 58 patients treated with either Invisalign Teen or Invisalign Full. Mandibular central and lateral incisors were measured on digital models created from intraoral scans. Predicted values were determined by superimposing the initial and final ClinCheck models, and achieved values were determined by superimposing the initial ClinCheck models and the digital models from the final scans. Individual teeth were superimposed with a best-fit analysis and measured using Compare software (version 8.1; GeoDigm, Falcon Heights, Minn).

Results: The mean accuracies of mandibular incisor intrusion were 63.5% in adolescents and 45.3% in adults, and this difference was statistically significant. The amounts of achieved intrusion were 1.7 mm in adolescents and 0.9 mm in adults, and this difference was also statistically significant. Overall, there was a weak negative correlation between age and accuracy; as age advanced, the accuracy of mandibular incisor intrusion diminished slightly.

Conclusions: Mandibular incisor intrusion with Invisalign is significantly more accurate in adolescents than in adults. Orthodontists could contemplate reducing the degree of overcorrection for mandibular incisor intrusion in adolescents with deep overbites undergoing Invisalign Teen but still implementing the reverse curve of Spee mechanics. (*Angle Orthod.* 0000;00:000–000.)

KEY WORDS: Invisalign; Invisalign Teen; Accuracy; Overbite; Intrusion

INTRODUCTION

Correcting a deep overbite with Invisalign can be challenging for orthodontists. Specifically, Invisalign struggles to achieve mandibular incisor intrusion, which remains one of its least accurate movements.^{1–8} Tooth movement studies conducted over the past 15 years have shown that the accuracy of mandibular incisor intrusion with Invisalign ranges from 25–45%.^{1–6} Thus, for many

patients with deep overbites receiving Invisalign, the results are often prolonged treatment with minimal overbite improvement.

There are several factors contributing to the lower accuracy of mandibular incisor intrusion with Invisalign. The most notable factors are patient noncompliance, loss of anchorage (aligner liftoff in the posterior region), and improper virtual case setup in ClinCheck. Although Invisalign has many perceived advantages compared to traditional labial braces for treating deep overbites, such as occlusal protection and avoidance of broken anterior brackets, its biomechanical disadvantages frequently offset them.

To improve biomechanical control, Align Technology introduced SmartForce features in 2008 and SmartTrack aligner material in 2011. Every few years, new SmartForce generational enhancements are released that improve the software, tooth movement sequencing, or attachment design and location. The popular fifth-generation (G5) enhancements, for example, aimed to improve deep overbite correction by creating maxillary anterior bite ramps and optimized premolar retention attachments.^{9,10}

Invisalign is currently on its eighth-generational (G8) enhancement, which partly aims to further improve

^a Private Practice, South Riding, Va, USA.

^b Private Practice, Durban, South Africa.

^c Private Practice, Mumbai, India; Adjunct Professor, Department of Orthodontics, Saveetha Dental College, Saveetha Institute of Medical and Technical Sciences, Chennai, India.

^d Private Practice, St Louis, Mo, USA.

^e Professor, Department of Orthodontics, Alexandria University, Alexandria, Egypt.

Corresponding author: Dr Neal D. Kravitz, Kravitz Orthodontics, 25055 Riding Plaza, Suite 110, South Riding, VA 20152 (e-mail: nealkravitz@gmail.com)

Accepted: October 2023. Submitted: May 2023.

Published Online: November 9, 2023

© 0000 by The EH Angle Education and Research Foundation, Inc.

Table 1. Descriptive Statistics

Parameter	Value
Age, years	
Adolescents	15.1
Adults	40.7
Gender	
Adult males	7
Adolescent males	9
Adult females	22
Adolescent females	20
Malocclusion	
Class I	41
Class II	14
Class III	3
Race	
Caucasian	38
Asian	16
African American	2
Hispanic	2
Invisalign	
Invisalign Full, number of patients	29
Invisalign Teen, number of patients	29
Invisalign Full, number of aligners (mean)	19.5
Invisalign Teen, number of aligners (mean)	23.0
Combined number of aligners (mean)	22.4

deep overbite correction.^{11,12} Some of its features include an optimized attachment for the mandibular lateral incisor, automated overcorrection of mandibular incisor intrusion, and automated placement of anterior bite ramps for mandibular incisor intrusion greater than 1.5 mm. Essentially, the software's algorithms and artificial intelligence now create compensation mechanisms for improved accuracy.

Despite these product advancements, orthodontists still recommend additional overcorrection of mandibular incisor intrusion in ClinCheck for treating deep overbites. In 2020, Kravitz et al.⁹ suggested implementing reverse curve of Spee mechanics, such as extrusion of the mandibular premolars and first molars and intrusion of the mandibular incisors and canines to create a simulated anterior open bite. That protocol corresponded to the results of the previous Invisalign tooth movement studies.¹⁻⁶

However, those previous studies¹⁻⁶ evaluated only adults, who had a combined mean age of 29.7 years, which poses the question "Is the accuracy of mandibular incisor intrusion different in adolescents?" If a difference exists, then this would influence the amount of recommended overcorrection. The purpose of this study was to compare the accuracy of mandibular

incisor intrusion with Invisalign in adolescents to that in adults. The null hypothesis stated that age would not influence deep overbite correction with Invisalign.

MATERIALS AND METHODS

The sample group comprised 58 patients (29 adults and 29 adolescents). The mean ages were 15.1 years in the adolescent group and 40.7 years in the adult group. There were 16 male and 42 female patients, including 38 Caucasian, 16 Asian, 2 African American, and 2 Hispanic patients, with 41 Class I, 14 Class II, and 3 Class III malocclusions. The total number of mandibular incisors measured was 232, including 116 central and 116 lateral incisors, and the mean number of aligners in the lower arch was 22.4 (Table 1).

The research protocol was approved by the institutional review board of the Saveetha Institute of Medical and Technical Sciences (IRB/SDC/F220-048). The ClinCheck virtual case setup and approval as well as the complete Invisalign treatment were provided by a single, experienced orthodontist (Dr Kravitz) (Tier-Level Diamond Plus provider with over 5,000 Invisalign cases treated) in private practice. A total of 66 consecutively treated Invisalign Teen or Invisalign Full patients were initially enrolled between January and April 2021. Data collection ended in June 2022.

Inclusion criteria were patients who (1) were aged 11 years or older, (2) received Invisalign Teen or Invisalign Full in both arches, (3) presented with a 4-mm overbite or greater, (4) completed initial and final scans, and (5) had confirmed good compliance. Exclusion criteria were (1) use of fixed appliances, (2) receipt of restorations before the final scan, (3) noncompliance, and (4) noncompletion. Eight patients were excluded: one converted to braces, one received restorations, and six did not receive a final scan in time.

An adolescent patient was defined as 11 to 19 years old. This corresponded to the allowable age range to receive Invisalign Teen as determined by Align Technology. An adult patient was defined as 20 years of age and older. Adolescent patients received Invisalign Teen, while adult patients received Invisalign Full. Except for the compliance tabs feature, there was no difference between Invisalign Teen and Invisalign Full other than nomenclature; they utilized the same aligner material and tooth movement sequencing.

Each patient received standardized ClinCheck instructions that implemented reverse curve of Spee mechanics,

Table 2. Accuracy of Mandibular Incisor Intrusion (%)^a

Age Group	Accuracy	SD	Min	Max	95% CI	Mean Difference	P Sig.
Adolescent	63.5	19.7	22.0	95.6	55.9–71.4	18.2	.003*
Adult	45.3	24.1	9.4	86.7	36.0–54.7		

^a SD indicates standard deviation; CI, confidence interval; Sig., Significance; * $P \leq 0.05$.

which read, "Bite ramps on the maxillary incisors. G5 attachments on the mandibular premolars and first molars. 4.0 mm horizontal beveled attachments on the mandibular lateral incisors and canines. Extrude the mandibular premolars and first molars 0.5 mm. Intrude the mandibular canines past the final position of the first premolar, and intrude the mandibular incisors past the final position of the canines. Finish with a 0.0 mm overbite and heavy posterior contacts. No interproximal reduction."

At the first Invisalign delivery appointment, all patients were instructed to wear their aligners for 22 hours per day and then advance to the new aligner at 1-week intervals.¹³ The patients were examined by the orthodontist (Dr Kravitz) at each visit to confirm compliance and distribute more aligners. After the patient completed all of their aligners, which typically involved two or three office visits, refinement scans were taken to create the final digital models for superimposition.

The patients' digital models were deidentified and imported into Compare (version 8.1; GeoDigm, Falcon Heights, Minn), a tooth measurement software program. According to the protocol established by Grünheid et al.,⁷ predicted values for mandibular incisor intrusion were determined by superimposing the initial and final ClinCheck models, and the achieved values were determined by superimposing the initial ClinCheck models and the digital models from the first refinement scans, using a geographical best-fit analysis.

Compare evaluated linear (millimeters) and angular (degrees) measurements in six directions (mesial-distal, facial-lingual, occlusal-gingival, tip, torque, and rotation); however, this study examined only linear measurements of gingival movement, or true intrusion, of the mandibular incisors. This step was taken to eliminate overbite correction from incisor proclination. Additionally, the results of mandibular incisor intrusion in this study were compared with the results from previous Invisalign tooth movement studies.¹⁻⁶

Statistical Analysis

Statistical analysis was performed using SPSS software (version 26; SPSS, Chicago, Ill). A Shapiro-Wilk test confirmed that the data were normally distributed. Independent *t*-tests ($P < .05$) compared the accuracies of mandibular incisor intrusion by age and tooth type.

Table 3. Amount of Predicted Intrusion (in mm)^a

Age Group	Predicted Intrusion	SD	95% CI	Mean Difference	<i>P</i> Sig.
Adolescent	2.6	0.8	1.15–0.26	0.7	.003*
Adult	1.9	0.8			

^a SD indicates standard deviation; CI, confidence interval; Sig., Significance; * $P \leq 0.05$.

Table 4. Amount of Achieved Intrusion (in mm)^a

Age Group	Achieved Intrusion	SD	95% CI	Mean Difference	<i>P</i> Sig.
Adolescent	1.7	0.8	1.17–0.33	0.8	.001*
Adult	0.9	0.8			

^a SD indicates standard deviation; CI, confidence interval; Sig., Significance; * $P \leq 0.05$.

The Pearson correlation coefficient was used to determine the relationship between age and accuracy. Clinical significance was set at 0.5 mm based on the American Board of Orthodontics (ABO) cast radiograph evaluation (CRE) as well as previous Invisalign studies.^{1,2}

RESULTS

The accuracies of mandibular incisor intrusion were 63.5% for the adolescent group and 45.3% for the adult group, and the difference (18.2%) was statistically significant ($P = .003$) (Table 2).

The amounts of predicted intrusion per tooth were 2.6 mm for the adolescent group and 1.9 mm for the adult group, and the difference (0.7 mm) was statistically significant ($P = .003$) (Table 3).

The amounts of achieved intrusion per tooth were 1.7 mm for the adolescent group and 0.9 mm for the adult group, and the difference (0.8 mm) was both statistically ($P = .001$) and clinically significant (Table 4). Thus, the adolescent group achieved a greater accuracy of intrusion despite having a larger predicted amount of intrusion.

Among tooth types, the accuracies of mandibular incisor intrusion were 52.1% for the central incisors and 56.5% for the lateral incisors, but the difference (4.4%) was not statistically significant ($P = .344$). The accuracies of intrusion for the mandibular central and lateral incisors were nearly identical (Table 5).

There was a weak but significant negative correlation ($r = -.218$, $P = .018$) between age and the accuracy of intrusion. In other words, with increasing patient age, there was a slight decrease in the accuracy of mandibular incisor intrusion (Figure 1).

DISCUSSION

Previous Invisalign tooth movement studies¹⁻⁶ conducted on adults showed that mandibular incisor

Table 5. Accuracy of Intrusion Between Tooth Types (%)^a

Tooth Type	Accuracy	SD	95% CI	Mean Difference	<i>P</i> Sig.
Centrals	52.1	24.7	13.5–4.8	4.4	.344
Laterals	56.5	24.1			

^a SD indicates standard deviation; CI, confidence interval; Sig., Significance; * $P \leq 0.05$.

intrusion was one of the least accurate movements. The low accuracy has remained constant despite advances in technology. In 2009, Kravitz et al.¹ reported an accuracy of 43.3%. In a follow-up study in 2020 using SmartTrack material and G5 SmartForce features on more complex cases, Haouili et al.² reported an accuracy of 35.3%. Similar results were later reported in 2021 by Al-Balaa et al.³ (37.8%) and Blundell et al.⁴ (39.2%).

The current study is the first prospective clinical study evaluating the efficacy of Invisalign in adolescents. The results showed that mandibular incisor intrusion was 18.2% more accurate in adolescents than in adults, rejecting the null hypothesis. In addition, the accuracy of mandibular incisor intrusion among adolescents surpassed the outcomes observed in the previous Invisalign studies,^{1–6} indicating that Invisalign's challenges with mandibular incisor intrusion might pertain predominantly to adults.

The higher accuracy in adolescents was even more impressive given that this group also had a larger amount of predicted intrusion. Adolescents had 2.6 mm of predicted intrusion and achieved 1.7 mm, whereas adults had 1.9 mm predicted and achieved only 0.9 mm. The findings in this study were virtually identical to those of Al-Balaa et al.³ (predicted, 1.9 mm; achieved, 0.8 mm) and Blundell et al.⁴ (predicted, 1.9 mm; achieved, 0.6 mm). It appears that 1 mm is the threshold for predictable mandibular incisor intrusion with Invisalign in adults.

This premise supports the use of reverse curve of Spee mechanics in this study since it incorporates posterior extrusion and incisor proclination. Goh et al.¹⁴ reported that Invisalign struggled to level the mandibular curve of Spee and advocated for overcorrection of mandibular first-molar extrusion, while Khosravi et al.⁸

reported that Invisalign achieved overbite correction by incisor proclination primarily. In straightforward terms, correcting a deep overbite with Invisalign should not depend solely on mandibular incisor intrusion.

To improve the accuracy of intrusion, horizontal attachments were placed on the lateral incisors. Oftentimes, the lower incisors fail to track during the simultaneous intrusion of the canines or when there is uneven alignment among the incisors. The similar accuracies between the central (52.1%) and lateral (56.5%) incisors in this study provided some validation for their use. Coincidentally, G8 SmartForce features now include automated placement of attachments on lateral incisors undergoing intrusion.¹¹

Some of the more interesting findings of this study were the large ranges for the accuracy of intrusion, particularly given that the protocol standardized the ClinCheck instructions and accounted for patient compliance during treatment. The range for the adolescent group was 22–96%, while the range for the adult group was 9–87%. Empirically, mandibular incisor intrusion with Invisalign can be successful in both adolescents and adults and also occasionally unsuccessful in both cohorts, but especially adults.

Overall, the results are best encapsulated by the negative correlation between age and the accuracy of intrusion. As age advances, the accuracy of intrusion diminishes slightly, with the starting point likely being the onset of puberty.¹⁵ This could be attributed to vertical ramal growth,¹⁵ molar eruption,¹⁵ and bone remodeling in adolescents or increased occlusal forces¹⁶ and enamel wear in adults. Regardless of the underlying factors, orthodontists should be receptive to considering Invisalign as an option for adolescents with deep overbite.

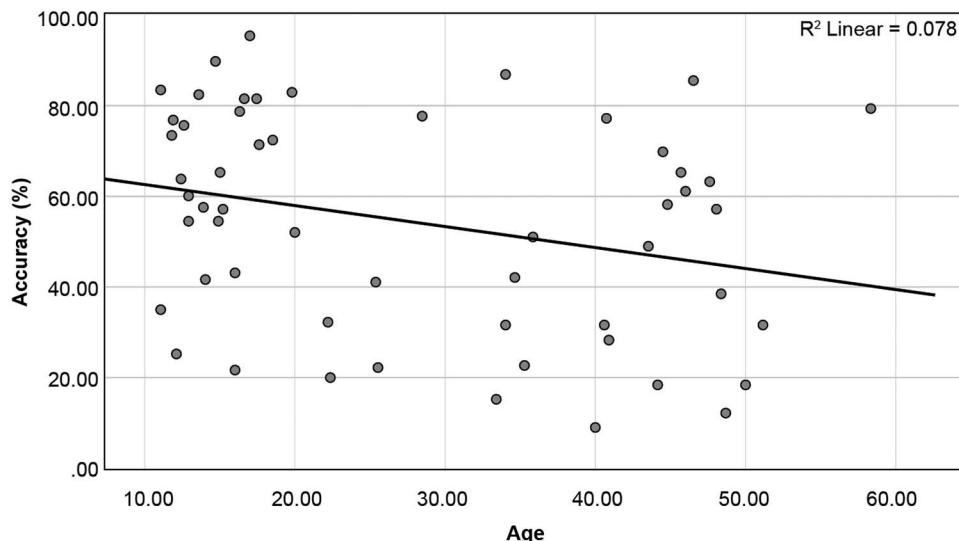


Figure 1. Plot of correlation between age and accuracy of intrusion.

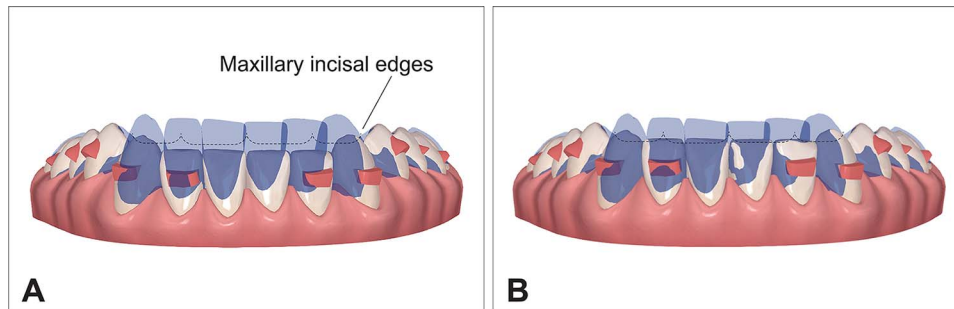


Figure 2. Implementation of reverse curve of Spee mechanics. More overcorrection of mandibular incisor intrusion could be considered in adults (A) compared with adolescents (B).

The clinical implications drawn from this study suggest that orthodontists could contemplate reducing the degree of overcorrection for mandibular incisor intrusion in adolescents presenting with deep overbite. To illustrate, orthodontists might treatment plan a simulated 0.5-mm overbite for adolescents while considering a 0.5-mm simulated open bite or greater for adults, accompanied by a more pronounced reverse curve of Spee (Figure 2A,B). Nevertheless, it is worth noting that hybrid mechanics involving lower braces might still be necessary for adult patients with severe deep overbite.¹⁷

Does the patient's age influence deep overbite correction with Invisalign? The evidence strongly suggests that it does.

The primary limitation with any Invisalign tooth movement study is that ClinCheck serves as a visual representation of forces and not as a predictor of final tooth position.¹⁸ This is especially true given the implementation of reverse curve of Spee mechanics. Therefore, 63.5% accuracy does not automatically translate to 63.5% clinical effectiveness. Additionally, despite the guidance by an Invisalign faculty member in writing the ClinCheck instructions, this study rests upon the proficiency of a single orthodontist.

CONCLUSIONS

- Mandibular incisor intrusion with Invisalign was significantly more accurate in adolescents than in adults. The mean accuracies of mandibular incisor intrusion were 63.5% in adolescents and 45.3% in adults.
- The amount of achieved intrusion was also significantly larger in adolescents than in adults. Adolescents achieved nearly twice as much mandibular incisor intrusion as adults.
- There was no statistical difference in the accuracies of intrusion between mandibular central and lateral incisors with horizontal attachments placed on the lateral incisors.

- As patient age advanced, the accuracy of mandibular incisor intrusion diminished slightly.

REFERENCES

1. Kravitz ND, Kusnoto B, BeGole E, Obrez A, Agran B. How well does Invisalign work? A prospective clinical study evaluating the efficacy of tooth movement with Invisalign. *Am J Orthod Dentofacial Orthop.* 2009;135:27–35.
2. Haouili N, Kravitz ND, Vaid NR, Ferguson DJ, Makki L. Has Invisalign improved? A prospective follow-up study on the efficacy of tooth movement with Invisalign. *Am J Orthod Dentofacial Orthop.* 2020;158:420–425.
3. Al-Balaa M, Li H, Ma Mohamed A, et al. Predicted and actual outcome of anterior intrusion with Invisalign assessed with cone-beam computed tomography. *Am J Orthod Dentofacial Orthop.* 2021;159:e275–e280.
4. Blundell HL, Weir T, Kerr B, Freer E. Predictability of overbite control with the Invisalign appliance. *Am J Orthod Dentofacial Orthop.* 2021;160:725–731.
5. Charalampakis O, Iliadi A, Ueno H, Oliver DR, Kim KB. Accuracy of clear aligners: a retrospective study of patients who needed refinement. *Am J Orthod Dentofacial Orthop.* 2018;154:47–54.
6. Krieger E, Seiferth J, Marinello I, et al. Invisalign treatment in the anterior region: were the predicted tooth movements achieved? *J Orofac Orthop.* 2012;73:365–376.
7. Grünheid T, Loh C, Larson BE. How accurate is Invisalign in nonextraction cases? Are predicted tooth positions achieved? *Angle Orthod.* 2017;87:809–815.
8. Khosravi R, Cohanin B, Hujuel P, et al. Management of overbite with the Invisalign appliance. *Am J Orthod Dentofacial Orthop.* 2017;151:691–699.
9. Kravitz ND, Moshiri M, Nicozisis J, Miller S. Mechanical considerations for deep-bite correction with aligners. *Semin Orthod.* 2020;26:134–138.
10. Henick D, Dayan W, Dunford R, Warunek S, Al-Jewair T. Effects of Invisalign (G5) with virtual bite ramps for skeletal deep overbite malocclusion correction in adults. *Angle Orthod.* 2021;91:164–170.
11. Moshiri M, Kravitz ND, Nicozisis J, Miller S. Invisalign eighth-generation features for deep-bite correction and posterior arch expansion. *Semin Orthod.* 2021;27:175–178.
12. Moshiri M. Product review and demonstration of the Invisalign clear aligner system. *Am J Orthod Dentofacial Orthop Clin Companion.* 2021;1:7–21.

13. Al-Nadawi M, Kravitz ND, Hansa I, Makki L, Ferguson DJ, Vaid NR. Effect of clear aligner wear protocol on the efficacy of tooth movement. *Angle Orthod.* 2021;91:157–163.
14. Goh S, Dreyer C, Weir T. The predictability of the mandibular curve of Spee leveling with the Invisalign appliance. *Am J Orthod Dentofacial Orthop.* 2022;162:193–200.
15. Baccetti T, Franchi L, Giuntini V, Masucci C, Vangelisti A, Defraia E. Early vs late orthodontic treatment of deepbite: a prospective clinical trial in growing subjects. *Am J Orthod Dentofacial Orthop.* 2012;142:75–82.
16. Usui T, Uematsu S, Kanegae H, Morimoto T, Kurihara S. Change in maximum occlusal force in association with maxillofacial growth. *Orthod Craniofac Res.* 2007;10:226–234.
17. Kravitz ND, Miller S, Bowman SJ, Wilmes B. Hybrid aligner treatment. *J Clin Orthod.* 2023;57:9–15.
18. Glaser BJ. *Insider's Guide to Invisalign Treatment: A Step-by-Step Guide to Assist You With Your ClinCheck Treatment Plans.* Sacramento, Calif: 3L Publishing; 2017.